



## ENDODONTIC RETREATMENT USING MTA-BASED SEALANTS IN A TOOTH WITH PERFORATION AND PERIAPICAL LESION

Nayara Rodrigues

*Master in Integrated Clinic with emphasis in endodontics and restoration of endodontically treated teeth. Specialist in Endodontics by Centro Universitário do Triângulo (UNITRI). Volunteer since 2015 in the extension project: Clinical care for patients in need of endodontic and restorative treatment in molar teeth. College degree in Dentistry by the School of Dentistry at Federal University of Uberlândia.*

### SUMMARY

Retreatment in teeth with root perforations can reduce the longevity of the treatment, because it depends on rapid location and proper sealing, with biocompatible materials that promote tissue repair. Therefore, the purpose of this clinical case report is to report an endodontic retreatment with presence of root perforation in the furcation region, and use of reparative cement and filling sealant based on mineral trioxide aggregate (MTA). Female patient, came to the dental office complaining of pain in the element 36, with indication of retreatment on it. Radiographically, it presented thickening of the periodontal ligament and periapical lesion in the mesial and distal roots, leading to the diagnosis of chronic apical periodontitis. After the first crown opening session, with the help of an operative microscope, it was possible to find a perforation in the most cervical portion in the furcation region of the mesio-vestibular root, which was covered by red resin. To treat this perforation, it was filled with MTA HP Repair, to enable preparation of root canals and subsequent filling with MTA Fillapex, through the Schilder Plus technique and execution of a 12mm relief on distal root for placement of the intra-radicular retainer. Rehabilitation of teeth with root perforations can be performed with MTA-based filling sealants, presenting satisfactory results for repairs in cases of perforations and periapical lesions, especially when associated with technologies such as operative microscope, which is an effective tool in the detection

and treatment of root perforations.

### INTRODUCTION

Root perforations are accidental unwanted complications that can occur in stages of the Endodontic treatment, as preparation of the access cavity and preparation of the root canal, or as a result of the extension of resorption or iatrogenic procedures<sup>1</sup>. Of these, 53% of iatrogenic perforations occur during the insertion of intra radicular retainers and the remaining 47% are induced during routine endodontic treatment<sup>2</sup>.

One of the most important causes of failure in endodontic treatment is the dental perforation at different places, among which the perforations in the furcation region have the worst prognosis. Perforations lead to inflammatory response in the periodontal region, which can cause irreversible damage of the periodontal ligament or even dental loss<sup>3</sup>.

The prognosis for endodontic perforations depends on the size and location of the defect and how quickly the perforated area was sealed with biocompatible material. A variety of materials such as zinc-oxide eugenol, amalgam, Cavit, composite resin, glass ionomer and mineral trioxide aggregate (MTA) have been suggested to seal these perforations<sup>2, 3, 4</sup>.

The introduction of MTA by Torabinejad in 1993 had a great impact on the endodontic practice, increasing the treatment success rates. In addition to its superior sealing properties, studies have shown that MTA has excellent biocompatibility when placed in contact with the periradicular tissues<sup>2, 5</sup>. It was initially recommended as filling material, but also features high success rates in pulp capping, pulpotomy, apical barrier formation in open apices and root perforation repair<sup>6</sup>.

The purpose of this clinical case report was to report an endodontic retreatment with presence of root perforation in the furcation region, in which reparative cement and filling sealant based on mineral trioxide aggregate (MTA) were used.

## CLINICAL CASE REPORT

Female patient, came to the dental office complaining of pain, for retreatment of element 36. Radiographically, it presented thickening of the periodontal ligament and periapical lesion in the mesial and distal roots, leading to the diagnosis of chronic apical periodontitis (Figure 1).

Through radiographies with angulation to mesial and distal it was possible to check the presence of 4 canals. In the first session, the following actions were performed: a crown opening, location of the canals and removal of the filling material with an ultrasound flat tip Irrisonic (Helse Dental Technology, São Paulo, Brazil). After 3 days, the patient returned and with the use of an operative microscope it was possible to locate the perforation in the most cervical portion in the furcation region in the mesiovestibular root, which was covered by red resin (Figure 2A). Intracanal medication based on calcium hydroxide (Biodinâmica Química e Farmacêutica, Paraná, Brazil) and a saline solution were used.

In the next session, the deviation in the mesio canal was filled with MTA HP Repair (Angelus Indústria de Produtos Odontológicos, Paraná, Brazil) and glass ionomer (S.S. White Duflex, Rio de Janeiro, Brazil) to enable performing the instrumentation of canals avoiding the expansion of the perforation (Figure 3).

In the same session, the remaining gutta-percha present in the distal canal was removed, electronic odontometrics was performed, and the tooth received calcium hydroxide intracanal medication (Biodinâmica Química e Farmacêutica, Paraná, Brazil).

With an interval of 4 weeks, patient asymptomatic, the working length was confirmed via apical and radiographic locator (Figure 4) and the perforation was filled again with MTA HP REPAIR (Angelus Indústria de Produtos Odontológicos, Paraná, Brazil) (Figure 5 and 6) in order to increase the perforation protection (Figure 2B). Medication was changed inside the canals.

After a month with medication, the total biomechanical preparation was performed, with Oregon technique and intracanal medication was provided

again. The patient returned after 15 days without pain, with presence of periapical repair, and the canals were filled with gutta-percha and sealant (Figure 7). MTA Fillapex (Angelus Indústria de Produtos Odontológicos, Paraná, Brazil), was applied using the Schilder Plus technique at the CDC adhesion level, and the distal canal was left with 12mm relief for placement of intra radicular retainer

After 7 months of follow-up, the patient does not present, clinically, pain symptoms and radiographically there was repair of bone resorption in the mesial and distal roots (Figure 8).

## DISCUSSION

The purpose of repairing a root perforation is to maintain a healthy periodontal, in juxtaposition with the perforation place, so that it is free of persistent inflammation and preventing or reestablishing the periodontal ligament insertion to nearby tissues. The success of the perforation repair depends on a good sealing of the perforated location with a biocompatible material and that it maintains the health conditions of the periodontal ligament<sup>7</sup>.

Some authors report that MTA can be used to repair root perforations with predictable results, since in examined cases, teeth did not present pathological changes after 12 to 45 months, and more than 82% of treated patients exhibited radiographic success with absence of pain<sup>8, 9, 10</sup>.

According to Siew 2015, in revision conducted with a total of 188 perforations included in the analysis, a success rate of 72.5% was concluded, regardless of the materials used, and of 80.9% for the use of MTA. These results suggested that non-surgical repair using MTA material can result in a higher success rate compared to other materials<sup>7, 11</sup>.

What differentiates MTA from other materials is its ability to promote the regeneration of the sealant, thereby facilitating the regeneration of the periodontal ligament. Therefore, it establishes an effective sealing of root perforations and can be considered a potential repair material that improves the prognosis of perforated teeth that otherwise would be compromised<sup>2, 11</sup>.

Therefore, the choice of the material used in this clinical case both for the perforation repair and the filling sealant was based on the most recent literature. The radiographic follow-up shows that the success of the case represents what is found by other writers, with

absence of pain, or periapical changes.

The ability to promote a proper sealing is a primary factor in the attempt to restore periodontal health<sup>2</sup>, and this must consider the technical skill and professional features and characteristics of the material used. The new formulations of the restorative sealant based on MTA facilitated the insertion of the material, mainly in small cavities or difficult access.

Burst perforations interfere in the dental element prognosis. The mesiovestibular root of the upper molars and the mesial root of the lower molars are highly susceptible to this type of perforation due to the thin root walls<sup>1</sup>. In addition to the limitation of sealing, the difficulty in determining the perforation location, its size and shape can be limiting for the case. Using microscope surgery is an effective tool in the detection and treatment of root perforations, and access to this technology was essential for the success of this case<sup>2</sup>.

## CONCLUSION

The reparative and filling sealant based on MTA, in its composition, has effective and satisfactory results in the treatment of root perforations, mainly when associated with technologies such as the operating microscope.

## AUTHORS' CONTRIBUTIONS

NR: elaboration of the article

LN: prosthetic rehabilitation of the clinical case, literature review

AM: literature review and photos of the clinical case

CM: implementation of the clinical case

GR: revision of article to the guidelines

MA: implementation of the clinical case and final revision of the article

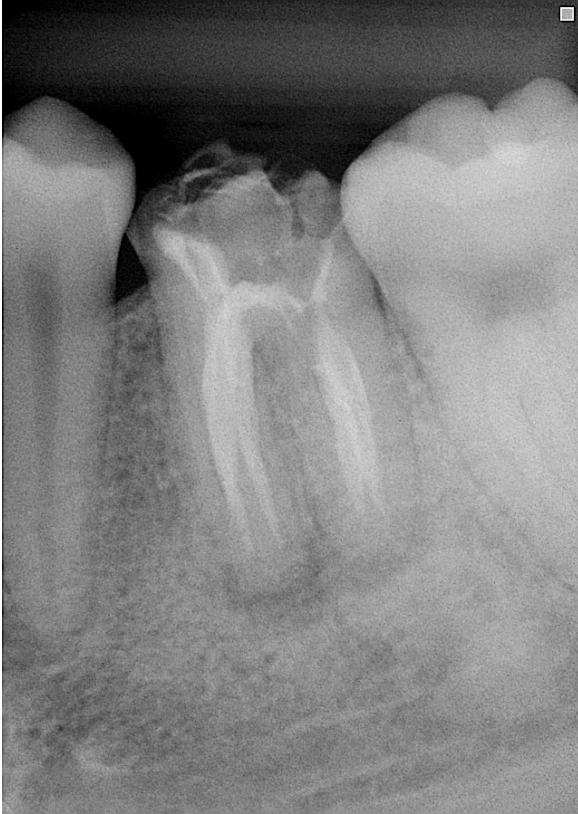
## REFERENCES

1. Froughreyhani M, Milani AS, Barakatein B, Shiezhadeh V. Treatment of a Strip Perforation Using Root MTA: A Case Report. *Iran Endod J.* 2013;8(2):80-83.
2. Nagpal R, Manuja N, Pandit IK, Rallan M. Surgical management of iatrogenic perforation in maxillary central incisor using mineral trioxide aggregate. *BMJ Case Rep.* 2013 Jul 10;2013.
3. Haghgoo 2013 Haghgoo R, Abbasi F. Comparison of ProRoot MTA and Root MTA in Repairing of Furcal Perforation of Primary Molars: A Laboratory Study. *Iran Endod J.* 2013; 8(2):52-54.
4. Unal GC, Maden M, Isidan T. Repair of Furcal Iatrogenic Perforation with Mineral Trioxide Aggregate: Two Years Follow-up of Two Cases. *Eur J Dent.* 2010 Oct;4(4):475-481
5. Asgray 2012 Asgary S, Motazedian HR, Parirokh M, Eghbal MJ, Kheirieh S. Twenty Years of Research on Mineral Trioxide Aggregate: A Scientometric Report. *Iran Endod J.* 2013;8(1):1-5.
6. Torabinejad M, Parirokh M. Mineral trioxide aggregate: a comprehensive literature review--part II: leakage and biocompatibility investigations. *J Endod.* 2010 Feb;36(2):190-202.
7. Siew K, Lee AH, Cheung GS. Treatment Outcome of Repaired Root Perforation: A Systematic Review and Meta-analysis. *J Endod.* 2015 Nov;41(11):1795-1804.
8. Parirokh M, Torabinejad M. Mineral trioxide aggregate: a comprehensive literature review--Part I: chemical, physical, and antibacterial properties. *J Endod.* 2010 Jan;36(1):16-27
9. Krupp C, Bargholz C, Brüsehaber M, Hülsmann M. Treatment outcome after repair of root perforations with mineral trioxide aggregate: a retrospective evaluation of 90 teeth. *J Endod.* 2013 Nov;39(11):1364-1368.
10. Parirokh M, Torabinejad M. Mineral trioxide aggregate: a comprehensive literature review--Part III: Clinical applications, drawbacks, and mechanism of action. *J Endod.* 2010 Mar;36(3):400-413.
11. Mente J, Leo M, Panagidis D, Saure D, Pfefferle T. Treatment outcome of mineral trioxide aggregate: repair of root perforations-long-term results. *J Endod.* 2014 Jun;40(6):790-196.
12. Wu D, Shi W, Wu J, Wu Y, Liu W, Zhu Q. The clinical

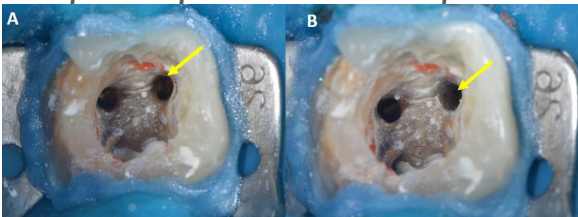
treatment of complicated root canal therapy with the aid of a dental operating microscope. IntDent J. 2011 Oct;61(5):261-266.

#### CAPTIONS OF THE FIGURES

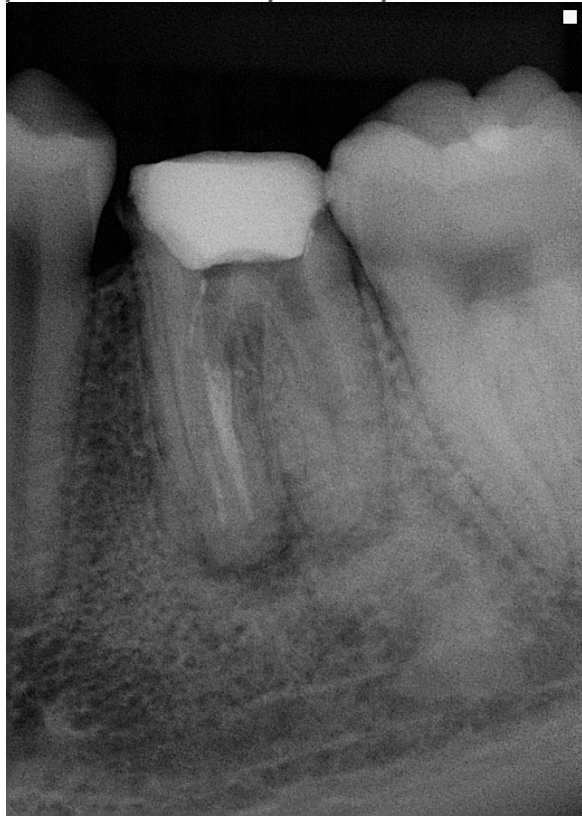**Figure1: Initial Radiography**



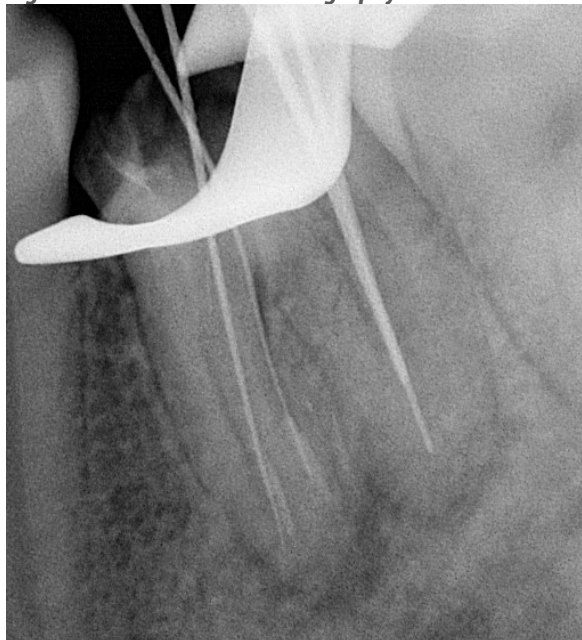
**Figure 2A: Initial aspect of the perforation**  
**2B: Aspect after placement of MTA HP Repair**



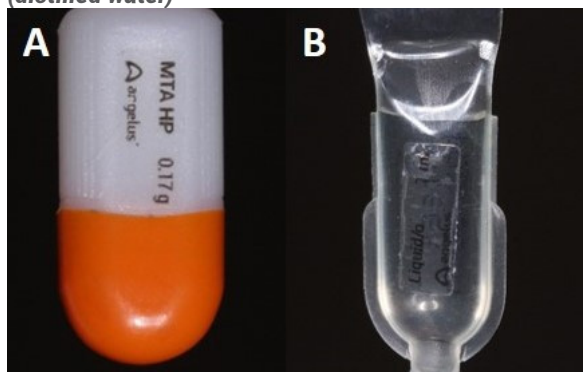
**Figure 3: Radiographic aspect after the placement of MTA HP Repair in the perforation**



**Figure 4: Odontometrics radiography**



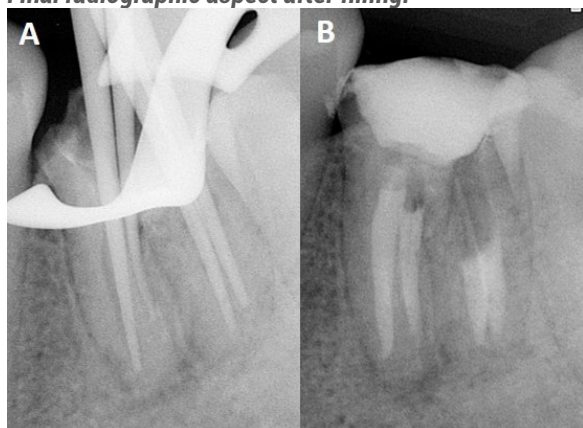
**Figure 5: Product used for sealing the perforation - MTA HP Repair Sealant (Angelus Indústria de Produtos Odontológicos) A. Powder capsule. B. Liquid (distilled water)**



**Figure 6: Manipulation of MTA HP Repair reparative sealant. A. Powder B. Liquid C. Insertion with MTA instrument**



**Figure 7: A. Cone beam radiography. B. Final radiographic aspect after filling.**



**Figure 8: Follow-up radiography after 7 months**

