

Bio-C[®] Repair

Bioceramic reparative material ready to use (putty)



History

Angelus was founded in 1994 in Londrina, Brazil. Since then, innovation has been the key aspect to developing products and building businesses. The company has continuously invested in Research and Development, maintaining a close relationship with Universities and National and International Research Centers in different areas of knowledge.

Angelus has been present in more than 80 countries, in America, Europe, Africa, Asia and Oceania. Our Quality Management System is ISO 13485:2016 and MDSAP certified, which demonstrates our ongoing commitment to maintaining the highest quality assurance standards in the industry. With worldwide regulatory clearances including US FDA, Health Canada, PMDA (Japan), COFEPRIS (Mexico) and Roszdravnadzor (Russia), Angelus has generated health smiles all around the world.

Back in 2001 Angelus launched MTA ANGELUS becoming the world's second company to place a bioceramic material on the market. Furthermore, it was the first company to launch a paste/paste bioceramic root canal sealer in 2010 (MTA-Fillapex).

From then on, the company has created a specific research line in order to increase the bioceramic products portfolio. Currently, new products have been launched and innumerable projects are still under development for different areas of dentistry.

Contents

INTRODUCTION	5
PRESENTATION	5
INDICATIONS	6
TECHNIQUES OF USE	8
Treatment of root or furcation perforations via canal	8
Treatment of root or furcation perforations via surgery	9
Treatment of internal reabsorption via canal	9
Treatment of communicating internal or external resorption via surgery ...	10
Retrofilling in endodontic surgery	10
Direct and indirect pulp capping	11
Apexification	11
Apexogenesis and pulpotomy	12
COMPOSITION/FORMULATION	13
TECHNICAL DATA	13
PHYSICAL AND CHEMICAL CHARACTERISTICS	14
Setting reaction	14
Radiopacity	15
Solubility	15
X-ray diffraction	16
Setting expansion	16
Average particle size	17
Chemical adhesion to dentin	17
Biocompatibility	18
MECHANISM OF ACTION	19
5 REASONS TO USE BIO-C® REPAIR	20
CLINICAL CASES	21
BIBLIOGRAPHY	21

INTRODUCTION

BIO-C® REPAIR is a bioceramic putty ready-to-use repair cement.

Besides the benefits of the bioceramic formulation as induction of tissue regeneration, bactericidal action and inhibition of bacterial infiltration, it presents a great advantage over traditional cements not requiring mixing. The ready-to-use presentation in a screw-in syringe facilitates the product removal to apply to the preparation site, simplifying this procedure with great time savings.

PRESENTATION



INDICATIONS

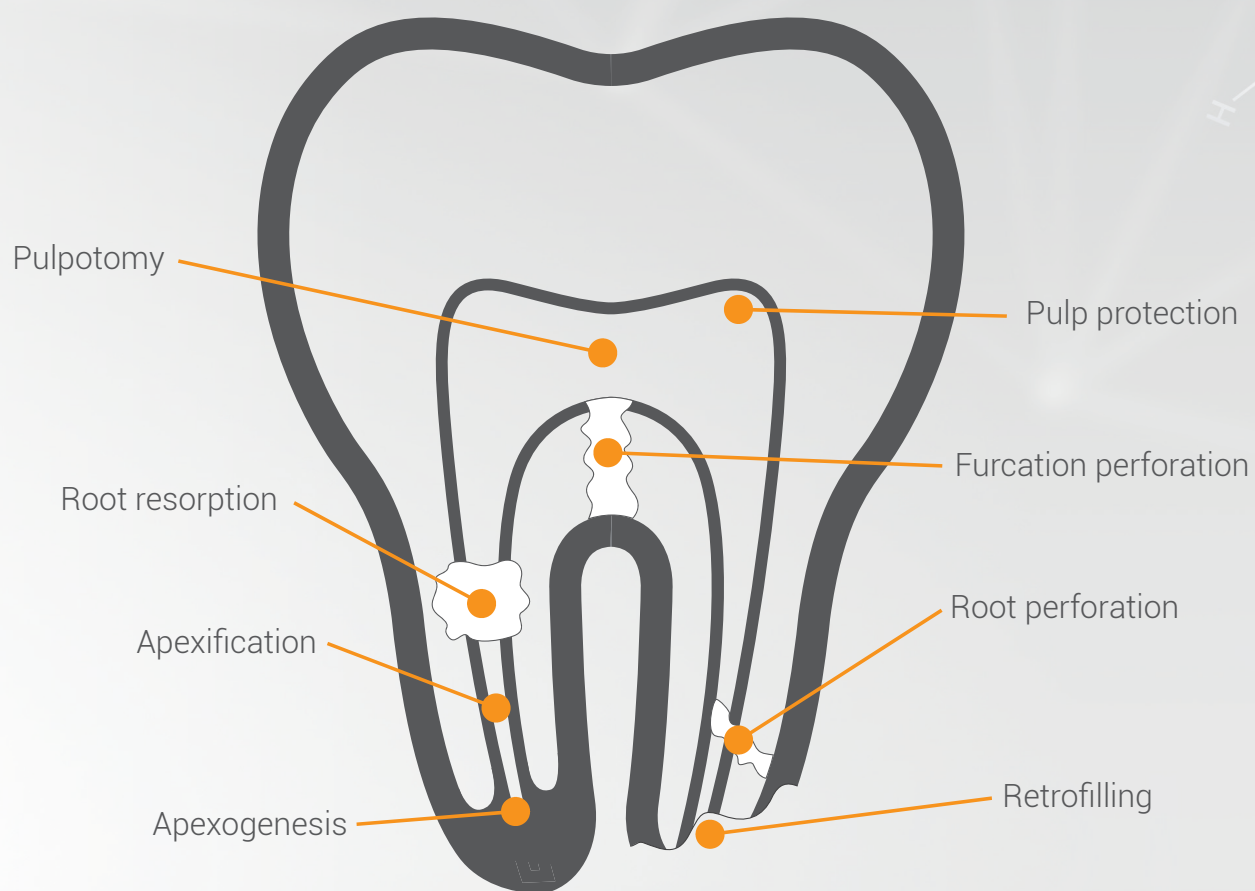
- A. Treatment of root or furcation perforation via canal;
- B. Treatment of root perforation or furcation perforation via surgery;
- C. Treatment of internal resorption via canal;
- D. Treatment of communicating internal or external resorption via surgery
- E. Retrofilling in endodontic surgery;
- F. Direct and indirect pulp capping;
- G. Apexification;
- H. Apexogenesis and pulpotomy;

The use of BIO-C® REPAIR in perforations presents the best results because, besides the physical seal provided by the expansion of the cement, it causes a biological seal by the formation of an intermediate layer of mineralization.

In cases of internal and external resorption, the high BIO-C® REPAIR pH, alkaline, neutralizes the acidity of the medium, preventing the progression of resorption.

For pulp capping and pulpotomy, BIO-C® REPAIR promotes the formation of a dentin barrier, which provides superior results than pure calcium hydroxide because the bioceramic is less soluble, has bactericidal action and hermetically seals the site due to its setting expansion.

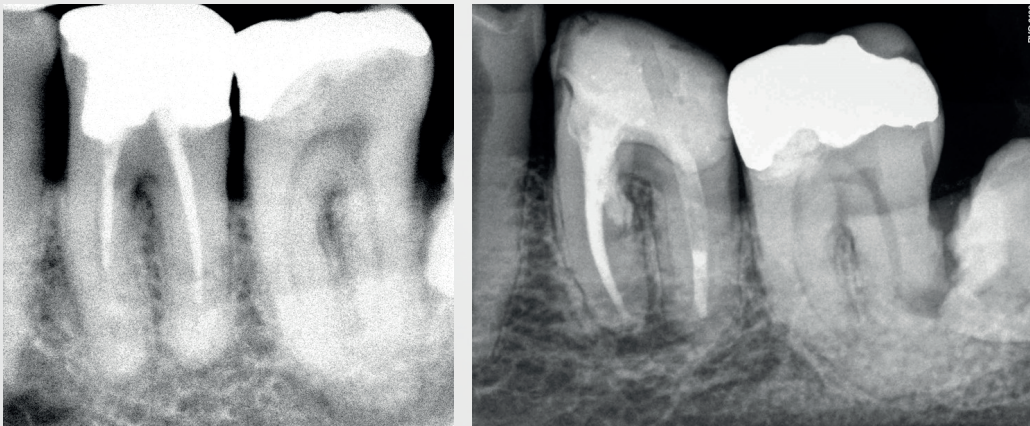
The use of BIO-C® REPAIR in the apexification of vital teeth with incomplete roots aims at keeping a healthy pulp and the Hertwig epithelial root sheath active in order to differentiate odontoblasts. Odontoblasts will produce dentin to continue root development resulting in roots with adequate thickness and, therefore, lower risk of fracture. This same process will also promote the formation of apical closure.



TECHNIQUES OF USE

Treatment of root or furcation perforations via canal

1. Anesthetize, install rubber dam isolation, perform biomechanical preparation of the canal and clean existing perforation;
2. Fill the canal in a conventional manner leaving the perforation exposed;
3. Perform haemostatic control and keep the cavity slightly moist;
4. Insert BIO-C® REPAIR and in case of extravasation, remove excess material;
5. X-ray to verify the correct placement of the material in the applied location;
6. Fill the remainder of the canal with gutta-percha cones and a sealant such as MTA-FILLAPEX or BIO-C® SEALER;
7. Perform coronary sealing and restoration.



Images courtesy of Dr. Cimara Barroso.

IMPORTANT:

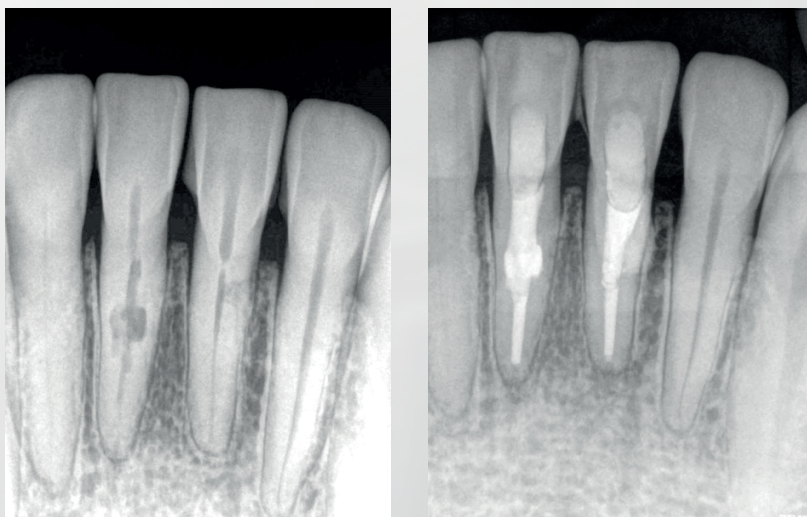
- *In furcation perforations apply a layer of glass ionomer as a mechanical barrier followed by restoration with definitive material;*
- *Do not use composite resin directly on BIO-C® REPAIR prior to its final setting.*
- *X-ray and follow for at least two years.*

Treatment of root perforation or furcation perforation via surgery

1. Anesthetize, elevate the gingival flap and do osteotomy to locate perforation;
2. Prepare the perforation with suitable instrument to facilitate the insertion of the material;
3. Perform haemostatic control and keep the cavity slightly moist;
4. Insert the BIO-C® REPAIR into the cavity, adapt with condensers and remove excess if it overflows;
5. Reposition the gingival flap and suture;
6. X-ray and follow for at least two years.

Treatment of communicating internal resorption or via canal

1. Anesthetize and install rubber dam isolation;
2. Remove granulation tissue from the resorption area;
3. Neutralize the medium with calcium hydroxide paste;
4. Remove calcium hydroxide in the next session and do the endodontic treatment in conventional way until resorption level;
5. Apply BIO-C® REPAIR to the resorption site, condensing it against the walls with specific instruments or a slightly moistened sterile cotton ball;
6. Perform coronary sealing with glass ionomer and restore with preferred material;
7. X-ray and follow for at least two years.



Teeth 31 and 41 - Internal resorption / Canal filled with BIO-C® REPAIR.
Images courtesy of Dr. Cimara Barroso.

Treatment of communicating internal or external resorption via surgery

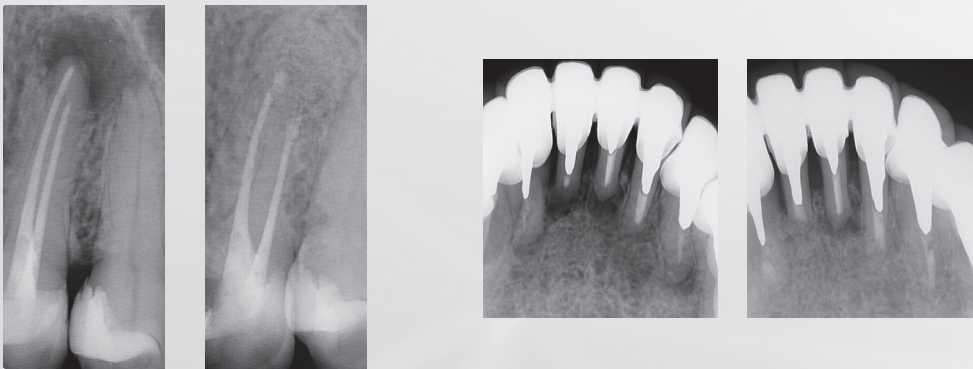
1. Anesthetize, elevate the gingival flap and do osteotomy to locate perforation;
2. Remove all affected cementum and dentin by removing the cells that cause resorption;
3. Do the hemostatic control, dry the cavity. It is advisable to condition the surface of the affected root preferably with citric acid;
4. Insert BIO-C® REPAIR into the cavity, which must be slightly moist; adapt the material with condensers and remove excess if it overflows;
5. Reposition the gingival flap and suture;
6. X-ray and follow for at least two years.

IMPORTANT:

BIO-C® REPAIR is not indicated in cases of external resorption above the bone crest.

Retrofilling in endodontic surgery

1. Anesthetize, elevate the gingival flap and do osteotomy to expose dental apex;
2. Section 3 mm of the root apex, which contains a large number of side canals (apical delta);
3. Do retro-preparation with appropriate instruments;
4. Perform hemostatic control and keep the cavity slightly moist;
5. Insert the BIO-C® REPAIR into the cavity, adapt with suitable condensers and remove any excess overflowed material;
6. Promote a bleeding site from the periodontal ligament and bone tissue, return the gingival flap to its position and suture;
7. X-ray and follow for at least two years.



Images courtesy of Dr. Vicente Rocha

Direct and indirect pulp capping

1. Anesthetize and install rubber dam isolation;
2. Remove decay; if there is pulp exposure, promote hemostasis;
3. Apply BIO-C® REPAIR to the cavity or to the pulp if exposed. Use appropriate instruments or a slightly moistened sterile cotton ball to set the material;
4. Cover BIO-C® REPAIR with a glass ionomer cement and wait 4 to 6 weeks to perform final restoration. Glass ionomer can be used as base of restoration.

WARNING: For deciduous or young permanent teeth with a large exposure, perform pulpotomy, and then go to steps 3 and 4 above.

Apexification

First Session

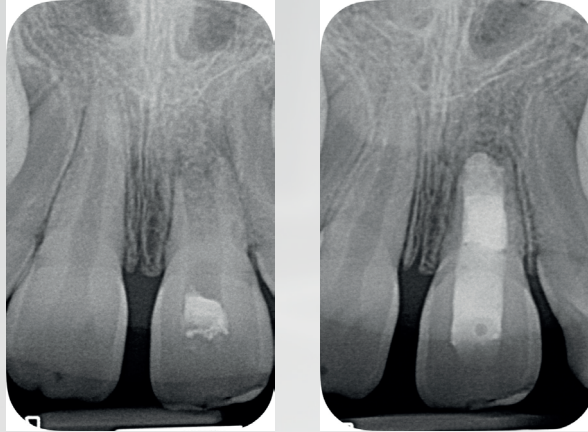
1. Anesthetize and install rubber dam isolation;
2. Prepare the canal by the conventional technique;
3. Apply an intracanal dressing with calcium hydroxide paste for one week.

Second Session

1. Remove intracanal dressing with files and irrigation solution;
2. Dry the canal with paper cones;
3. Make a mechanical barrier in the apical region to prevent extravasation of BIO-C® REPAIR. It is advisable to use a collagen sponge or similar products.
4. Apply BIO-C® REPAIR by condensing it to form an apical plug of 3 to 4 mm;
5. X-ray to verify the correct filling of the canal;
6. Place a lightly moistened cotton ball in the canal entrance followed by temporary restoration.

Third Session

1. Remove the temporary restoration and fill the canal to the limit of the apical plug;
2. Restore with glass ionomer;
3. Perform clinical and radiographic control for 3 to 6 months until radiographic visualization of the formation of an apical barrier of hard tissue.



Images courtesy of Dr. Mário Zuolo.

Apexogenesis and pulpotomy

1. Anesthetize, install rubber dam isolation then access the pulp chamber;
2. Remove the roof from the pulp chamber and excise the coronary pulp with sharp curettes or drills;
3. Cut the pulp 0.5 mm below the entrance of the root canal;
4. Wash the surgical wound thoroughly with distilled water, saline, or specific detergent;
5. Perform hemostasis and keep the cavity slightly moist;
6. Apply BIO-C® REPAIR on the pulp stump and adapt with a slightly moistened sterile cotton ball;
7. X-ray to verify the correct filling of the canal;
8. Restore cavity provisionally with glass ionomer;
9. Perform clinical and radiographic control for 3 to 6 months until the radiographic view of the root formation;
10. After the end of the root formation, opt for conventional endodontic treatment or only the restoration of the coronary endodontic cavity.

COMPOSITION/FORMULATION

COMPONENT	FUNCTION
Tricalcium Silicate (C ₃ S)	Mechanical resistance over time Calcium ions release
Dicalcium Silicate (C ₂ S)	Mechanical resistance over time Calcium ions release
Tricalcium Aluminate	Initial setting
Calcium Oxide	Calcium ions release
Zirconium Oxide	Radiopacity
Silicon Oxide	Rheology agent
Polyethylene Glycol	Dispersing agent
Iron Oxide	Pigmentation

TECHNICAL DATA

Setting Time	≤ 120 minutes
Radiopacity	≥ 7.0 mm Al
pH	≈ 12
Size of Particles	< 2 µm
Solubility	Inferior to 3%
Setting Expansion	0.092 ± 0.05%
Resistance to Compression	7.933 ± 3.284 MPa

PHYSICAL-CHEMICAL CHARACTERISTICS

Setting reaction

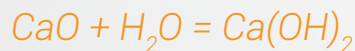
The setting time of BIO-C® REPAIR will depend on the presence of moisture at the site it has been applied to the tooth structure. Water molecules present in the medium come in contact progressively with the particles of BIO-C® REPAIR, causing hydration, setting of the cement and release of the active ions. These chemical reactions involve the hydration of Calcium Silicate compounds to produce a hydrated Calcium Silicate (C-S-H) gel, responsible for setting and formation of calcium hydroxide, according to the following equations:



Tricalcium Silicate + Water = C-S-H + Calcium Hydroxide



Dicalcium Silicate + Water = C-S-H + Calcium Hydroxide



Calcium Oxide + Water = Calcium Hydroxide

The formed Calcium Hydroxide dissociates rapidly into ions Ca^{2+} and OH^- , increasing the pH of the medium, and consequently, making the environment inhospitable for bacterial growth. On the other hand, the Calcium ions will react with the CO_2 present in the bloodstream, forming Calcium Carbonate. An extracellular matrix rich in fibronectin is secreted when in contact with these products, triggering the formation of a hard tissue. Histologically, the stimulation for the deposition of this tissue is observed through Calcite granulations, around which there is great condensation of fibronectin, which provides cell adhesion and differentiation.

The setting process is attributed to the Hydrated Calcium Silicate gel crystals that bind and bypass the aggregates (radiopacifier) giving the product mechanical strength. The setting time is related to the humidity availability in the medium and will occur around 120 minutes*.

*Tests were performed according to ISO 6876:2012.

Radiopacity

The product presents radiopacity ≥ 7 mm in the Aluminum, in accordance with ISO Standard 6876:2012.

The radiopacifier present in the product formula is Zirconium Oxide which, unlike other radiopacifiers used in Dentistry, does not promote tooth staining.

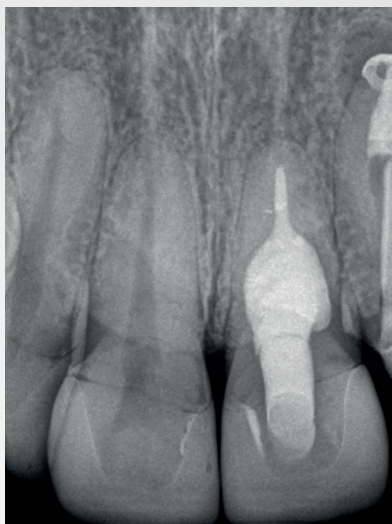


Image courtesy of Dr. Vanessa Pandolfi.

Solubility

The solubility of BIO-C® REPAIR, according to the tests carried out by ISO Standard 6876:2012, presented the following results:

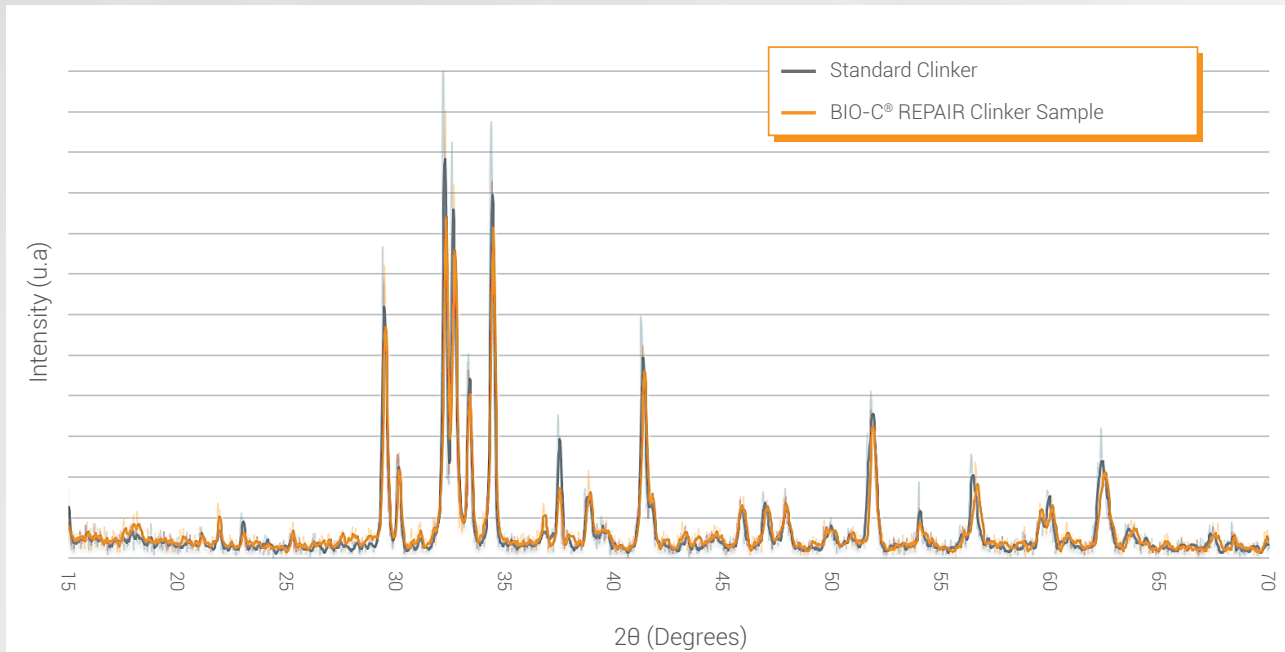
Solubility and desintegration of BIO-C® REPAIR

SAMPLES	%
1	0.42
2	0.36
3	0.38
Average	0.39
Standard deviation	0.03

BIO-C® REPAIR showed low solubility, a desirable and favorable result for a product with the purpose of repairing and sealing dental structure cavities.

X-ray diffraction

These trials confirm the presence of Calcium Silicates, Calcium Oxide and Tricalcium Aluminate in the composition of BIO-C® REPAIR. The presence of these crystalline structures is fundamental for the product to reach the ideal physical and biological properties.

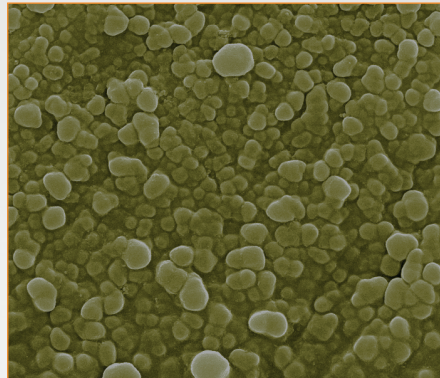


Setting expansion

BIO-C® REPAIR exhibits setting expansion equal to $0.092 \pm 0.05\%$, unlike most dental materials undergoing contraction. The setting expansion of this product prevents bacterial infiltration, property that is of paramount importance to avoid recontamination and, consequently, endodontic failure.

Average particle size

BIO-C® REPAIR has a particle size of $< 2 \mu\text{m}$. Micronization improves rheological properties of the product, promoting penetration into the dentinal tubules. The reduced particle size makes the product more reactive, which favors the faster release of Ca^{2+} ions and OH^- ions associated with the healing process of endodontic lesions.



Images courtesy of Dr. Celson Klein.

Chemical adhesion to dentin

The contact of BIO-C® REPAIR with moisture and tissue fluids releases active ions that interact with the organic and inorganic matrix of the dentin, promoting the formation of an intermediate area, called the Mineral Infiltration Zone (MIZ). This area of mineral infiltration in the dentin provides an excellent biological seal, minimizing possibilities of bacterial infiltration, that would lead to recontamination and endodontic failure.

Biocompatibility

The BIO-C® REPAIR is a bioceramic restorative cement composed of Calcium Silicates classified as "device with long-term external communication", that is, for more than 30 days (ISO Standard 7405). Based on this classification, and in compliance with the standards, cytotoxicity, skin irritation and sensitization tests were performed.

Cytotoxicity (ISO 10993-5)

The study of the cytotoxic potential of BIO-C® REPAIR was performed *in vitro* using V-79 fibroblasts cell line. Cell viability was determined by the incorporation of MTT. The cytotoxicity presented is due to the high pH of the material, around 12, intentionally developed to render the environment inhospitable to bacterial proliferation.

In the presence of moisture, the formed Calcium Hydroxide raises the pH making the alkaline medium. Alkaline pH has a destructive effect on protein structures and can promote enzymatic denaturation as well as damage to the cell membrane.

However, the occurrence of chemical irritation by similar materials, such as Calcium Hydroxide, does not cause irreversible damages to the tissues. In practice, the presence of a non-extensive inflammatory process in underlying pulp and periapical tissues actually, leads to stimulation of tissue repair *.

Skin irritation and reactivity (ISO 10993-10)

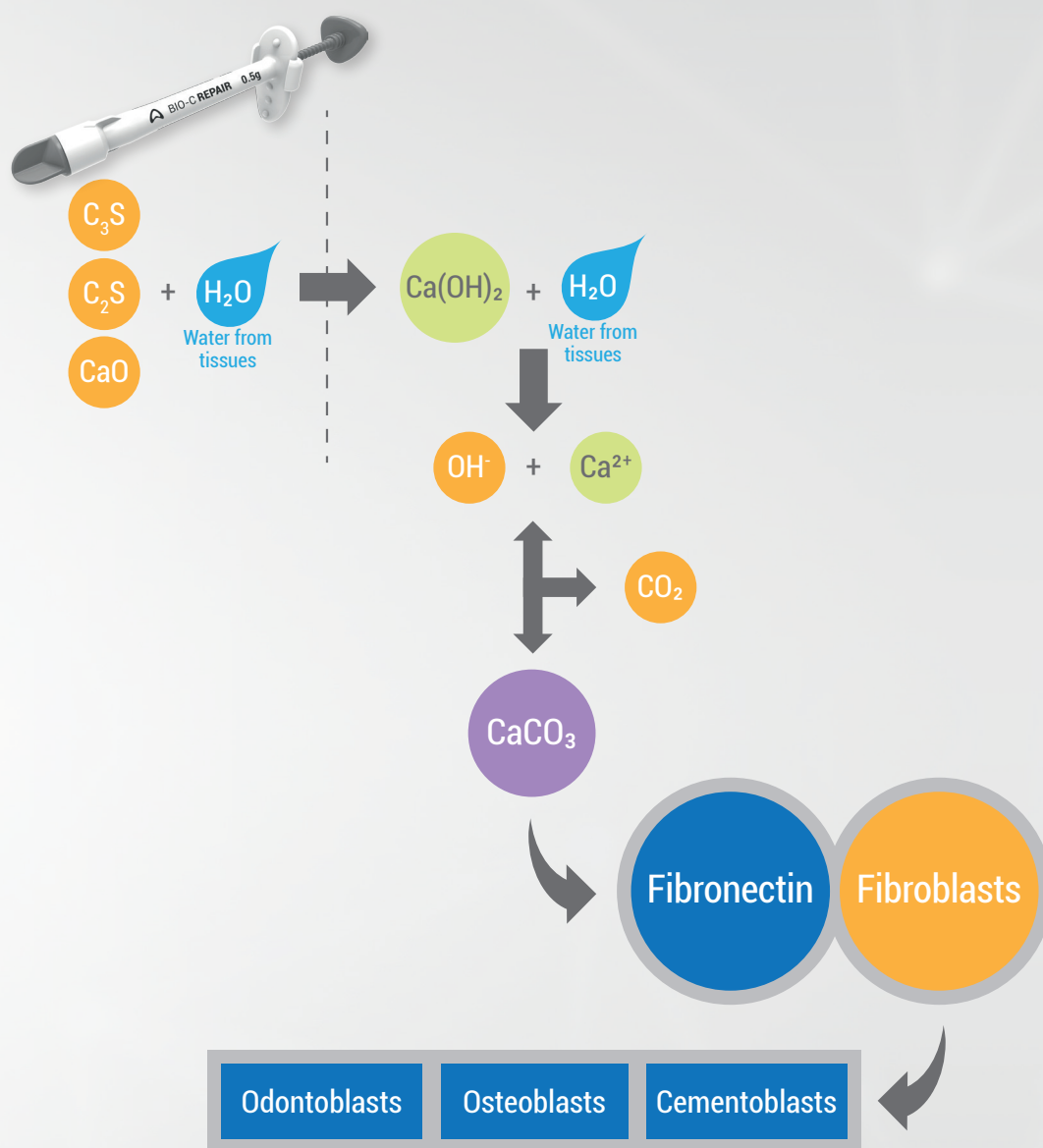
The possible irritant effects of BIO-C® REPAIR were evaluated according to ISO 10993-10. Studies were conducted on oral mucosa of Syrian Hamsters. No macroscopic or microscopic changes were observed. The index of irritation obtained from the histopathological analyzes was null. It was therefore concluded that, under the study conditions, BIO-C® REPAIR was classified as non-irritant to the oral mucosa of hamsters.

Skin sensitization (ISO 10993-10)

Cutaneous sensitization studies were conducted in CBA / J lineage mice according to ISO 10993-10, which determined that a sensitizing material induced lymphocyte proliferation in the lymph node near the site of application. Lymphocyte proliferation was assessed, by determining the incorporation of bromodeoxyuridine (BrdU) into the DNA of lymph node cells. According to the results obtained by the ELISA method, the stimulation index was 1.55. It is therefore concluded that BIO-C® REPAIR is classified as a non-sensitizing material.

*Yoshino, P.; Nishiyama, C.K.; Modena, K.C.S.; Santos, C.F.; Sipert, C.R., "In Vitro Cytotoxicity of White MTA, MTA-Fillapex® and Portland Cement on Human Periodontal Ligament Fibroblasts", Brazilian Dental Journal (2013) 24 (2): 111-116..

MECHANISM OF ACTION



The mechanisms of action of BIO-C® REPAIR are closely associated with contact with tissue moisture and fluids. After the Calcium Oxide, present in the formulation of BIO-C® REPAIR, comes into contact with the water present in the dentin tubules, Calcium Hydroxide is formed. Calcium Hydroxide also interacts with the fluids, dissociating in Calcium ion and Hydroxyl. The Hydroxyl ions are responsible for the pH increase, promoting bactericidal action of the product. The released Ca^{2+} ions react with CO_2 from the bloodstream, forming Calcium Carbonate (Calcite). An extracellular matrix rich in fibronectin is secreted as a result of the alkaline pH and attracted by Calcite, triggering the formation of hard tissue. Histologically, stimulation occurs to the deposition of this hard tissue, through granulations of Calcite, around which there is great condensation of fibronectin, which provides cell adhesion and differentiation.

3

Reasons to use BIO-C[®] REPAIR

1

Ready-to-use/putty

Easy to use and insert into cavity.

2

High release of calcium ions

Stimulates tissue regeneration.

3

High alkalinity (pH ~ 12)

Bactericidal action.

Repair and Regeneration!

CLINICAL CASES

Clinical Case 1

Endodontic Microsurgery as a Complementary Treatment of Endodontic Retreatment of Canals with Silver Cone Filling

Prof. Dr. Leandro A. P. Pereira

Professor of Endodontics at the School of Dentistry - São Leopoldo Mandic
Master and PhD in Pharmacology, Anesthesiology and Medical Therapy – UNICAMP
Specialist in Endodontics - Operative Microscopy – Inhalation Sedation

Endodontic retreatment is indicated in cases of failure of an anterior endodontic treatment. The main objective of endodontic treatment and retreatment is to clean and disinfect the entire extension of the root canal system to a healthy level (Siqueira et al., 2000). When, through meticulous treatment, such goals are achieved, success rates can exceed 94% (Imura et al., 2007; Lazarski et al., 2001).

In order to clean the root canal system to achieve the best prognosis of a retreatment, an important step is the complete removal of the root canal filling obtaining a new access to the apex. Inadequate canal cleaning, especially of the apical third, predisposes to endodontic failure (Sjogren et al 1990, Nair PN et al 1990). In some clinical situations such as the presence of pins and core, separate instruments and silver cones, free access to the apex is not always easy. In fact, it is one of the most difficult surgical procedures in Endodontics.

These materials, especially metal materials, can cause severe obstructions blocking the passage of an endodontic instrument. Intentionally leaving part of these materials in the canal can lead to insufficient endodontic disinfection. Failure to remove endodontic obstruction may result in poor cleaning, shaping, and filling of the root canal system. These clinical situations potentially decrease the success rate of retreatment. Considering this microbiological issue, the attempt to remove these materials should always be performed (Gluskin et al 2008).

Silver cones were used and indicated as root canal filling material. However, they have been showing corrosion in humid environments. The byproducts of this chemical reaction can cause blemishes and inflammation in the surrounding tissues, especially in the periapical area. In addition, the lack of plasticity does not allow its good adaptation to the walls of the root canal. This makes them a less suitable filling material. Today, new materials and contemporary techniques can provide much better options.

In making the decision to remove a silver cone, factors such as periapical diagnosis, location, root curvature, length, silver cone size, coronal extent, remaining dentin thickness, and iatrogenic risks during the attempt should be considered.

One technique commonly used to remove these materials is to establish a bypass with manual file. In this way, the fragment can be extracted from the pulp chamber and then removed. Another technique of removal is the use of an ultrasonic vibration in the fractured fragment, associated with the use of a dental operation microscope. Silver cones are very delicate and fragile. The application of ultrasonic vibration can cause the instrument to split. Therefore, the vibration power should be adjusted below 20%. This low vibration can disengage the silver cone from the channel wall, and then be extracted from the pulp chamber and finally removed. Combined techniques such as bypass and ultrasonic have been commonly used in modern Endodontics.

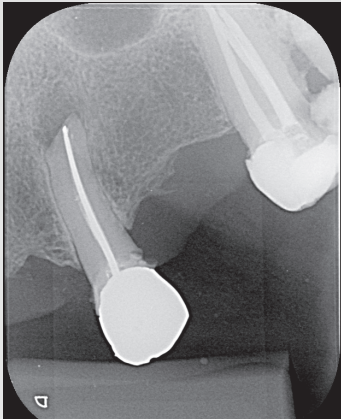
However, procedural errors may occur during endodontic procedures. Yousuf W et al. 2015 made a digital radiographic evaluation of 1748 teeth treated endodontically and found procedural errors in 32.8% (574 teeth) of them. In endodontic retreatment with the presence of the silver cone, a common technical complication is the rupture of a silver cone. These accidents may compromise the treatment and prognosis of the clinical case. In these situations, additional procedures are required to resolve the problem.

CLINICAL CASE

A 68-year-old female patient, ASA I, pulse of 64 bpm, BP 116 X 68 mmHg, SpO₂ 98%, temperature 36.5°C, arrived at the dental office complaining of constant low intensity spontaneous pain in the buccal and apical area of tooth 23 (Figure 1). She presented an intraoral edema, pain during mastication and vertical percussion.

She reported having undergone endodontic treatment on tooth 23 more than 35 years ago. In the periapical radiographic examination, it was possible to visualize an ineffective endodontic treatment, with an endodontic obturation with silver cone and the presence of symptomatic apical periodontitis. An acute apical abscess was diagnosed.

Figura 1- Initial radiography



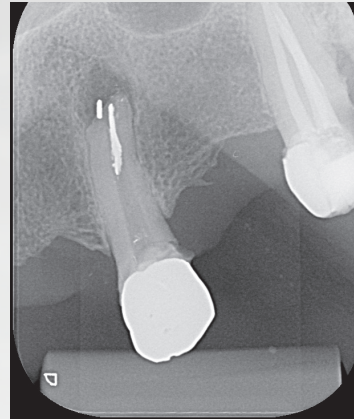
The proposed treatment was endodontic retreatment, because in the previously performed treatment there was an inadequate cleaning and molding of the canal, leading to an endodontic filling with cavities, keeping the infection intracanal. Endodontic microsurgery was contraindicated due to the presence of insufficient anterior endodontic treatment.

Endodontic retreatment began with access to the pulp chamber using a Predator Turbo Dental Drill (Angelus - Londrina - Brazil). The cement around the silver cone rod was removed with an E7D ultrasonic tip (Helse Ultrasonic-Brazil) (Figure 2). After exposing the coronary part of the silver cone, an E5 - Long Ultrasonic Tapered Tip (Helse Ultrasonics - Brazil) was used to vibrate the silver cone body. Although there was a low ultrasonic power adjusted to 15%, separation occurred (Figure 3). Due to the lack of adaptation of the obturation material in the apical third, part of the silver cone fragment was removed from the periapical lesion.

Figure 2 - View of the obturated canal of the coronary part of the silver cone

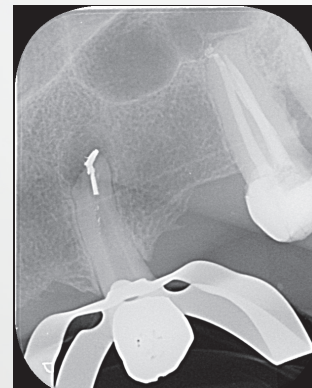


Figure 3 - First separation of the silver cone



Root canal modeling was done using Reciproc R25 File (VDW - Germany) followed by Reciproc Blue RB50 File (VDW - Germany). During endodontic retreatment, abundant irrigation with 2.5% of sodium hypochlorite was done. After several attempts to remove the remaining part of the silver cone, another separation occurred (Figure 4). Part of the silver cone was removed from the canal. However, the other fragment could not be removed.

Figure 4 - Expulsion of the silver cone

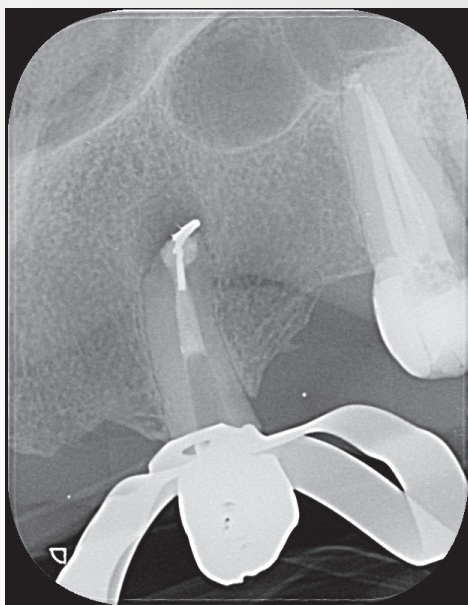

At this stage of treatment, adequate disinfection control had not been achieved. The presence of the fragment did not allow an appropriate disinfection of the root canal. Because of this, the spontaneous pain, although diminished, did not cease. As a result of failure to properly control infection, a complementary surgery was proposed to remove the apical fragment. Before entering microsurgery, the root canal was completed.

Endodontic retreatment of the filled canal was performed with a final rinse with 17% EDTA passively activated ultrasonically, followed by root canal obturation using gutta-percha cones with BIO-C®

REPAIR (Angelus - Brazil). BIO-C® REPAIR is a new ready-to-use Bioceramic Endodontic Cement. It can be placed directly from the syringe into the root canal. The gutta-percha cones were compacted with a vertical cold compaction technique (Figure 5).

Figure 5 – Endodontic obturation



After conventional endodontic retreatment, the patient underwent an apical microsurgery. Osteotomy and apicoectomy were performed using an ultrasonic tip (W1-CVDentus-Brazil). The apical fragment of the silver cone became visible at a magnification of 12.5x (Figure 6). In order to remove the apical fragment, a P1M Ultrasonic Tip (Helse Ultrasonic - Brazil) was used (Figure 7, Figure 8). After the microsurgical removal of the silver cone, a retrograde preparation was performed with the same ultrasonic tip (Figure 9).

Figure 6 - Apical third after apicectomy

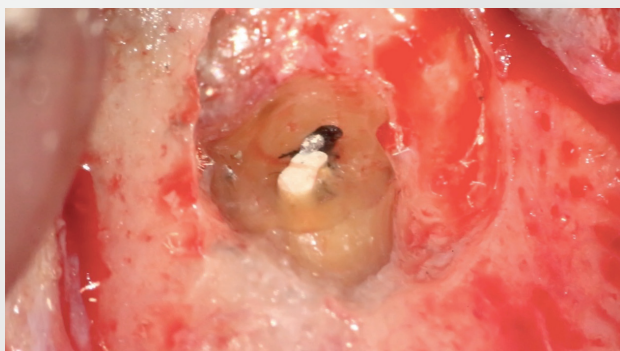


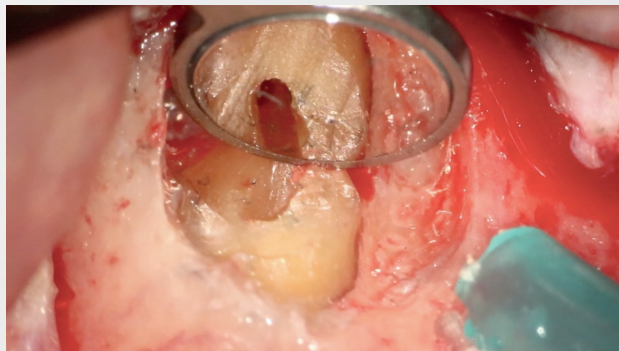
Figure 7 - Microsurgical removal of the silver cone

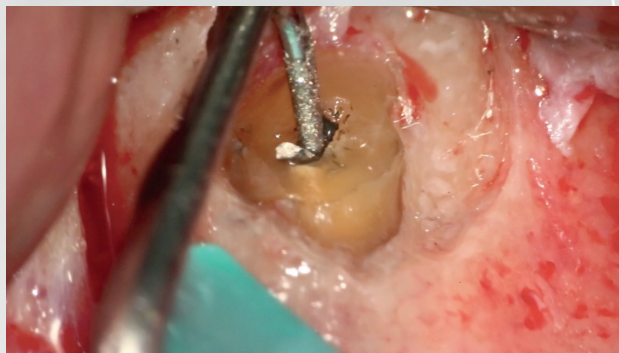

Figure 8 - Surgical removal of the silver cone

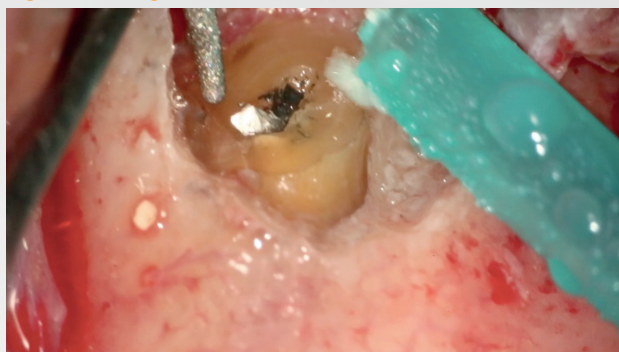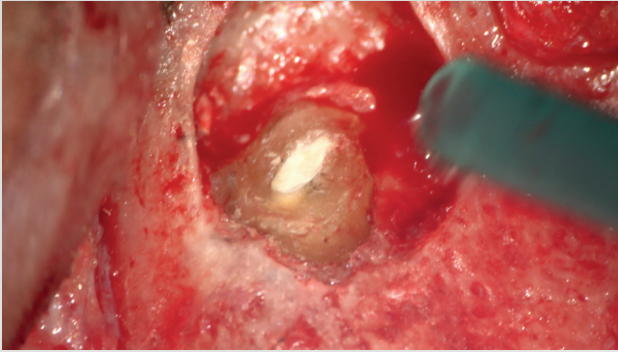
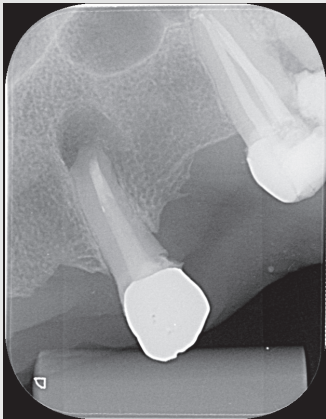


Figure 9 - Retrograde preparation

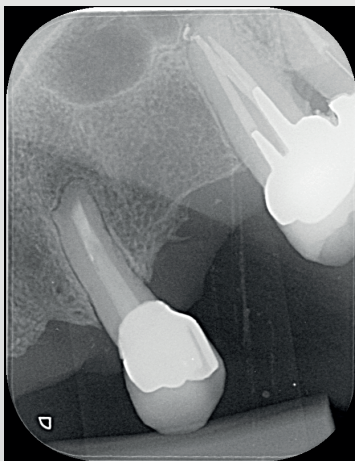


MTA, a bioceramic material, was used as the first choice for retrograde fillings. Its superior characteristics of marginal adaptation, biocompatibility, cementing capacity in humid environments, induction and conduction in the formation of hard tissues, cementogenesis and consequent formation of normal periodontal adhesion, makes the material more suitable for these clinical situations. In this case, new bioceramic materials were used to obturate the retrograde cavity. First, BIO-C® REPAIR (Angelus - Brazil) was used to fill the space in the root canal. An apical BIO-C® REPAIR plug (Angelus - Brazil) was placed on top of the root, sealing the retro cavity (Figure 10, Figure 11).

F

Figura 10 – Retrograde filling**Figura 11 – X-ray immediately after surgery**

The 6-month follow-up showed very rapid bone healing. Clinically, she no longer had any signs or symptoms of endodontic disease (Figure 12). Rapid bone healing may be related to the release of calcium from this new bioceramic repair material containing calcium tungstate as a radiopacifier instead of Bismuth Oxide from its predecessor (conventional MTA). In addition, the size of the bioceramic particles are smaller than that of the MTA, allowing more contact with the surrounding tissues, increasing the biological response.

Figure 12 – Follow-up after 6 months

CONCLUSION

Proper cleansing and root canal system modeling are of utmost importance for successful endodontic therapy. The presence of an obliterating object within the root can compromise the prognosis of the case. It is therefore extremely important to eliminate these obstacles.

However, depending on the severity of the case, some obstructions cannot be removed with a sealed canal treatment. In these situations, a complementary microsurgical approach may be required. Postoperative radiography and clinical control of this clinical case show that complementary microsurgery may be a safe and predictable clinical option.

REFERENCES

- Imura N, Pinheiro ET, Gomes, BPFA, Zaia AA, Ferraz CCR, Souza-Filho CCR. "The outcome of endodontic treatment: a retrospective study of 2000 cases performed by a specialist." *J Endod.* 2007; 33(11):1278-1282.
- Lazarski M, Walker W, Flores C, Schindler W, Hargreaves K. "Epidemiological evaluation of the outcomes of non-surgical root canal treatment in a large cohort of insured dental patients." *J Endod.* 2001; 27(12):791-796.
- Siqueira J, Lima K, Magalhães F, Lopes H, de Uzeda M. "Mechanical reduction of the bacterial population in the root canal by three instrumentation techniques." *J Endod.* 1999; 25:332-335.
- Sjogren U, Hagglund B, Sundqvist G, Wing K. "Factors affecting the long-term results of endodontic treatment." *J Endod.* 1990; 16:498-504.
- Nair PN, Sjogren U, Krey G, Kahnberg KE, Sundqvist E. "Intraradicular bacteria and fungi in root-filled, asymptomatic human teeth with therapy-resistant periapical lesions: a long-term light and electron microscopic follow-up study." *J Endod.* 1990; 16:580-588.
- Gluskin AH, Peters, CI, Ming Wong RD, Ruddle CJ. "Retreatment of non-healing endodontic therapy and management of mishaps." In: Ingle JI, Bakland LK, Baumgartner C, editors. *Text book of Endodontics*. 6th ed. Hamilton, Ontario, USA: BC Decker; 2008. pp. 1088-61.
- Yousuf W, Khan M, Mehdi H. "Endodontic Procedural Errors: Frequency, Type of Error, and the Most Frequently Treated Tooth." *Int J Dent*. vol. 2015, Article ID 673914, 7 pages, 2015.
- Souter NJ, Messer HH. "Complications associated with fractured file removal using an ultrasonic technique." *J Endod.* 2005; 31(6):450-452.
- Spili P, Parashos P, Messer HH. "The impact of instrument fracture on outcome of endodontic treatment." *J Endod.* 2005; 31(12):845-850.
- Predebon JC, Flório FM, Basting, RT. "Use of CVDentUS Diamond Tips for Ultrasound in Cavity Preparation." *J Contemp Dent Pract.* 2006; 7(3):50-58.
- Labanca M, Azzola F, Vinci R, Rodella LF. "Piezoelectric surgery: twenty years of use." *J Oral Maxillofac Surg.* 2008; 46:265-269.
- Preti G, Martinasso G, Peirone B, Navone R, Manzella C, Muzio G, Russo C, Canuto RA, Schierano G. "Cytokines and growth factors involved in the osseointegration of oral titanium implants positioned using piezoelectric bone surgery versus a drill technique: a pilot study in minipigs." *J Periodontol.* 2007; 78:716-722.

Clinical Case 2

Internal Radicular Resorption

Dr^a Vanessa Pandolfi Pessotti

DDS, Specialist in Endodontics by CEO - IPSEMG - MG

Master in Endodontics by UERJ - RJ - Microscopic Endodontics

ABSTRACT

Internal resorption represents an inflammatory pulpopathy that develops after pulp aggression, with consequent focal necrosis of odontoblasts associated with a chronic inflammatory condition, but without loss of pulp vitality. In order for internal resorption to occur, a chronic pulpal inflammatory process is necessary and, therefore, the pulp cannot evolve into necrosis. Its etiology is related to traumatism, cavities, chronic pulpitis, and deep instability. As it has no symptoms, it is diagnosed through routine radiographic examinations, where we observe that the contour of the pulp boundaries undergoes a relatively symmetrical expansion, giving rise to a radiolucent image, with balloon appearance and regular contours. The present article reports a case of internal root resorption involving the root of a left upper incisor tooth. Endodontic treatment was performed in two sessions, with the use of intracanal calcium hydroxide medication, conventional obturation of the apical third with gutta-percha, filling of the resorptive cavity with BIO-C® REPAIR (Angelus, Londrina, Brazil) and resin restoration. With the treatment performed, a good clinical result was obtained, allowing the tooth to be maintained in the alveolus.

INTRODUCTION

Root resorption is the loss of hard dental tissues as a result of clasto-type cell activities (Patel 2007; Patel et al., 2010). It can be a physiological or pathological phenomenon. Resorption in the primary dentition is a normal physiological process, except when resorptions occur prematurely (Bille et al., 2007; Batel et al., 2008; Patel et al., 2010), whereas pathological resorptions are not observed naturally in no stage of life of the individual. According to the affected dental surface, it can be classified into internal resorptions, when they start in the walls of the pulp cavity; when they begin on the external root surface; and internal-external when the resorptive process is established in the internal and external root surfaces, occurring the communication between the areas of resorption. Generally, in cases of internal-external resorption it is not possible to identify in which dental surface the process started (Consolaro 2012; Lopes & Siqueira Jr. 2010).

Internal reabsorption is considered to be a pulpopathy of inflammatory nature, the process of which generates a chronic response to pulp tissue (Patel et al., 2010). The pathology originates in the interior of the pulp chamber or in the root canal and is characterized by a destruction of the dentin that begins in the pulp in a dentin wall, progressing in the internal-external sense. It occurs inside the pulp cavity, in a centrifugal way, towards the outer surface of the crown or root (Ferreira et al., 2007). With the evolution of the disease, perforation of the wall of the root canal can occur, leading to a communication of the dental pulp with the periodontium. Radiographically, this pathology is characterized by a uniformly visible radiolucent enlargement in the root canal, with a relatively symmetrical expansion of ballooning and regular contours (Consolaro 2012; Cohen & Hargreaves 2011).

In physiological conditions, the pulp wall is protected from the action of the clasts by the odontoblasts and pre-dentin layers, which prevent them from contacting the mineralized dentin. Odontoclasts are multinucleated cells that attach only to mineralized tissues, destroying them if they are able to. In order for internal root resorption to occur, the external protection of the odontoblasts layer and the pre-dentin of the root canal wall must be damaged, resulting in exposure of the mineralized dentin underlying the odontoclasts (Trope 1998; Patel et al., 2010).

There are several factors that cause internal resorption, including trauma, dental caries, deep restorations and chronic pulpitis (Lopes & Siqueira Jr. 2010; Patel et al., 2010). In trauma, the dislocation of odontoblasts occurs, exposing the mineralized dentin to the action of odontoclasts (Ferreira et al., 2007). When the dentin surface is exposed, the clasts adhere firmly to the brush by creating a micro-environment between the clasto and the mineralized surface, triggering the resorption process (Ferreira et al., 2006). In chronic pulpitis associated with caries and deep restorations, part of the odontoblastic layer is absent, exposing the mineralized dentin directly to the pulp connective tissue. In these situations, these areas of dentin exposure may be the starting point of internal resorption (Consolaro 2012; Ferreira et al., 2007; Cohen & Hargreaves, 2011).

Henemann et. al. (2003) estudaram a prevalência da reHenemann et. al. (2003) studied the prevalence of internal root resorption in permanent teeth and its location in the pulp cavity using a radiographic file with one hundred and fifteen radiographs containing this pathology. The results showed that the highest prevalence occurred in the upper incisors and the middle third of the root canal was the most common location. Also, a significant number of cases with

perforation were observed. This result may be associated with a greater presence of trauma in this region than in other areas, since the etiological factor related to trauma is the most prominent one.

The diagnosis of pulpal changes requires a systematic approach by the patient, including clinical examination, anamnesis and complementary examinations. From the interaction between these factors it is possible to identify the disease and, thus, to establish the treatment plan to be performed. Early diagnosis of internal root resorption is essential to achieve treatment success.

In the initial stage, conventional X-ray is not efficient to diagnose root resorptions (Prata et al., 2002). It is very important to do a good periapical radiography; and when possible, request a cone beam computed tomography (CBCT) to confirm the diagnosis and to evaluate whether the internal resorption is communicating or not.

Internal resorptions may be located in the radicular or coronary portion of the tooth. When present in the crown, internal reabsorption gradually approaches the enamel and, through transparency, the presence of a pink or reddish point or area, a pathognomonic sign of this pathology (Consolaro 2012; Cohen & Hargreaves, 2011) is evident.

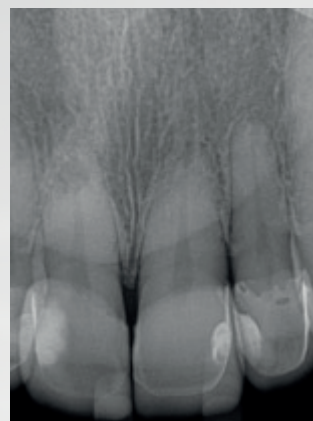
In the treatment of cases of internal root resorption, the Endodontist must perform a rigorous chemical-mechanical preparation, seeking physically and chemically to reach all walls of the resorption. After cleansing and modeling, both the canal and the resorbing cavity must be filled three-dimensionally to prevent bacterial recontamination.

The objective of this study is to report a clinical case of internal root resorption without periodontal communication involving the upper left incisor, demonstrating that it is possible to obtain good clinical results from an early diagnosis and an appropriate treatment, allowing the maintenance of the tooth in the alveolus.

CLINICAL CASE

A 44-year-old female patient came to the practice to undergo endodontic treatment. We performed initial radiography to evaluate tooth 22 and we came across a radiolucent balloon image, characterizing an internal root resorption in tooth 21. We then performed a new radiograph to evaluate tooth 21 (Figure 1).

Figure 1 - Initial radiograph



During anamnesis, the patient reported having suffered a butt from her son two years ago. Clinical examination revealed presence of porcelain facet on tooth 21, positive pulp sensitivity test, absence of symptomatology and absence of alterations in the gingival mucosa. We asked for a cone beam computed tomography (Figures 2, 3 and 4) to confirm the diagnosis, to evaluate whether the resorption was communicating or not, and to study the remaining tooth structure.

Figure 2 - Tomographic image - coronal section

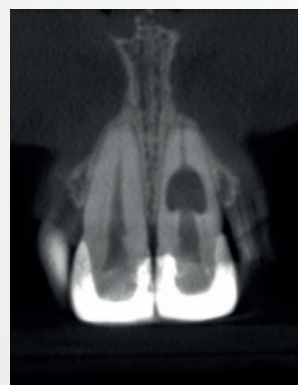

Figure 3 - Tomographic imaging - axial section

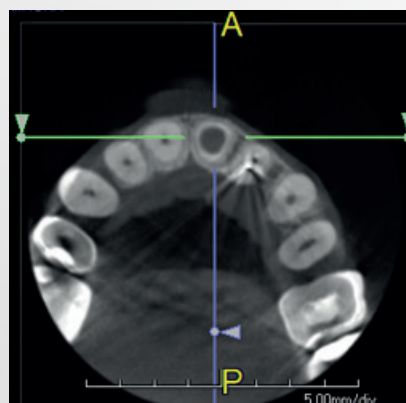
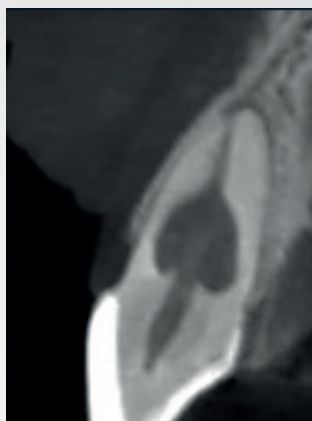


Figure 4 - Tomographic image - sagittal cut

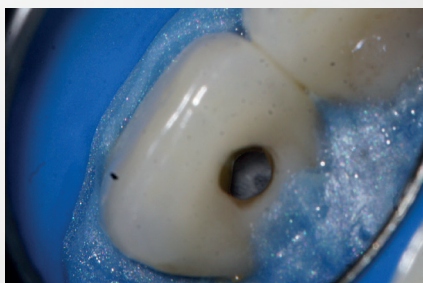

The use of CBCT can be invaluable in the decision-making process. The scanned data provide the clinician with a three-dimensional appreciation of the tooth; the extent and location of resorption; the adjacent anatomy; the presence or absence of root perforations and allows us to evaluate whether the lesion is amenable to treatment (Tyndall 2008; Patel et al., 2010).

After the clinical, radiographic and tomographic analysis, the diagnosis of internal root resorption was established without external communication, which makes the prognosis more favorable.

After the access, the canal was irrigated with 5% Sodium Hypochlorite followed by 17% EDTA, both with PUI and Easy clean. Through the use of the operative microscope, it was possible to visualize the extent of the resorptive cavity (Figure 5). During the chemical-mechanical preparation, we conducted abundant irrigation with auxiliary chemical substances with effective organic solvent capacity and spherical ultrasonic tip to remove and dilute the remaining pulp tissue.

Figure 5 - Resorptive cavity

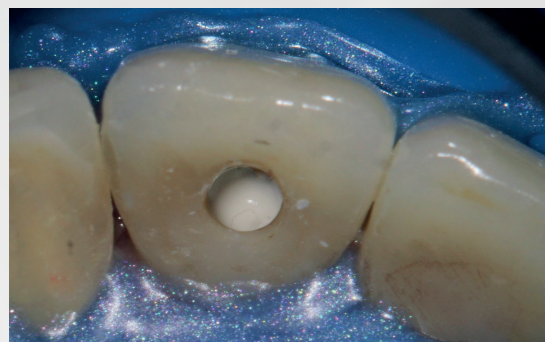

Due to the inaccessibility of internal root resorption walls, debridement, chemical-mechanical preparation and ultrasonic activation of irrigators should be seen as an essential step in disinfecting the internal resorption defect. However, even with the use of ultrasonic instruments, bacteria, in infected cases, can remain in confined areas. Thus, an intracanal antibacterial drug should be used to improve the

disinfection of inaccessible walls (Burleson et al., 2007; Patel et al., 2010).

The canal was then filled with a Calcium Hydroxide PA (Pro-Analysis) paste with saline (Figure 6) to chemically cauterize the tissue, which might still be present in the cavity, and to promote the necrosis of all osteorplasty units as a function of its high pH and alkalization of the medium, thus ceasing the clastic activity.

Figure 6 - Intracanal medication



In the second session, 15 days later, we performed conventional obturation of the apical third of the canal with gutta-percha, filling the reabsorbing cavity with BIO-C® REPAIR (Angelus, Londrina - Brazil) (Figure 7, 8 and 9), condensing it against the walls with specific condensers and moistened cotton ball and made the coronary sealing with resin.

BIO-C® REPAIR is a ready-to-use bioceramic repair cement. It is composed of calcium silicate, calcium aluminate, calcium oxide, zirconium oxide, iron oxide, silicon dioxide and dispersing agent. BIO-C® REPAIR has superior characteristics of marginal adaptation, biocompatibility, excellent radiopacity and sealing capacity in humid environments. In addition to these characteristics, it has as great advantage its ease of insertion into the resorptive cavity.

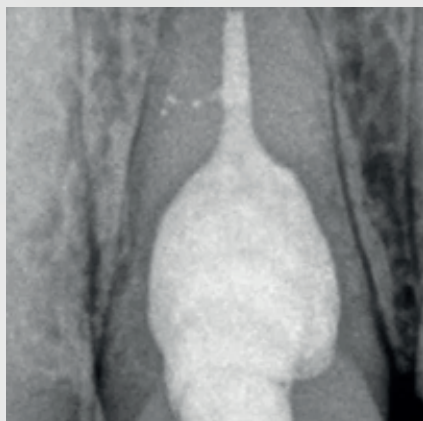
Figure 7 - BIO-C® REPAIR (Angelus, Londrina - Brazil).

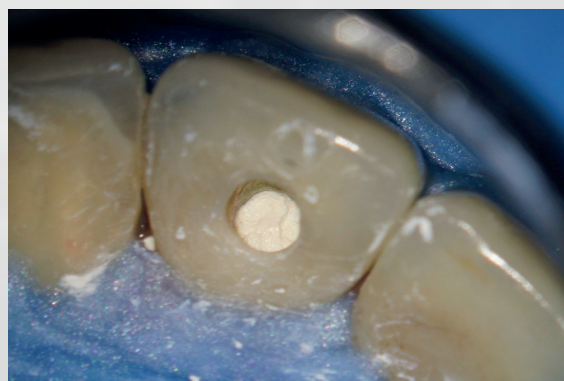

Figure 8 - Final radiography

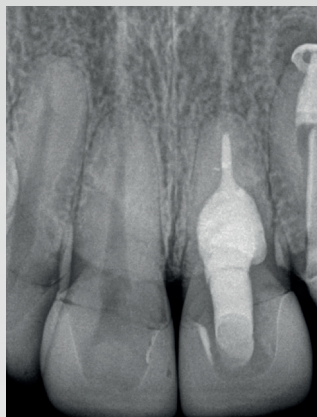

Figure 9 - Resorptive cavity filled with BIO-C® REPAIR



CONCLUSION

It is very important to carry out good anamnesis, clinical and complementary exams. Because the earlier the diagnosis of internal root resorption, the better the prognosis, reducing the risk of fragility of the dental structure. It is possible to obtain good clinical results from early diagnosis and appropriate treatment, allowing the maintenance of the tooth in the alveolus.

REFERENCES

- Bille ML, Kvetny MJ, Kjaer I. A possible association between early apical resorption of primary teeth and ectodermal characteristics of the permanent dentition. *Eur J Orthod* 2008; 30:346-51.
- Bille ML, Nolting D, Kvetny MJ, Kjaer I. Unexpected early apical resorption of primary molars and canines. *Eur Arch Paediatr Dent* 2007; 8:144-9.
- Burleson A, Nusstein J, Reader A, Beck M. The in vivo evaluation of hand/rotary/ ultrasound instrumentation in necrotic, human mandibular molars. *J Endod* 2007; 33:782-7.
- Cohen S, Hargreaves KM. *Caminhos da polpa*. 10. ed. Rio de Janeiro: Elsevier, 2011. 928 p.
- Consolaro A. *Reabsorções dentárias nas especialidades clínicas*. 3. ed. ampliada e revisada. Dental Press, 2012. 816 p.
- Ferreira, MM, Carrilho, EVP, Leitão J. Mecanismo e classificação das reabsorções radiculares. *Rev. Portuguesa de Estomatol. Med. Dent. Cir. Maxilofac.* (Elsevier Doyma), v. 47, n. 4, 2006.
- Ferreira, MM, Carrilho, EVP, Leitão J. Reabsorção radicular interna. *Rev. Portuguesa de Estomatol. Med. Dent. Cir. Maxilofac.* (Elsevier Doyma), v. 48, n. 2, 2007.
- Henemann, BM et al. Reabsorção dentinária interna: um estudo da prevalência em dentes permanentes. *Stomatos, Canoas*, v.9, n.16, 2003.
- Lopes, H, Siqueira Júnior, JF. *Endodontia: biologia e técnica*. 3. ed. Rio de Janeiro: Guanabara Koogan, 2010. 690 p.
- Patel, S. Is the resorption external or internal? *Dent Update* 2007; 34: 218-29.
- Patel, S, Ricucci D, Tay F. Internal root resorption: a review. *J Endod* 2010; 7: 1107-21.
- Prata, MIA, VILLA N, Rodrigues, HA, Cardoso, RJA. Avaliação da reabsorção radicular apical externa e interna em dentes com lesões periapicais. *JBE, Curitiba*, v.3, n.10, p.222-28, jul./set. 2002.
- Tronstad L. Root resorption: etiology, terminology and clinical manifestations. *Endod Dent Traumatol* 1988; 4: 241-52.
- Trope M. Root resorption of dental and traumatic origin: classification based on etiology. *Pract Periodontics Aesthet Dent* 1998; 10:515-22. 41.
- Tyndall DA, Rathore S. Cone-beam CT diagnostic applications: caries, periodontal bone assessment, and endodontic applications. *Dent Clin North Am* 2008; 52: 825-41.

Clinical Case 3**Ready-to-use bioceramic materials in apical resorptions****Dr Ricardo Afonso Bernardes***Dentistry, University of Uberaba (1990).**Endodontics, School of Dentistry of Bauru, University of São Paulo.**Master in Endodontics (2002), Doctorate in Endodontics (2013)**School of Dentistry of Bauru, University of São Paulo. Visiting and postdoctoral professor at the University of British Columbia, Vancouver, 2013.**Professor and Director, Endodontics, School of Dentistry, Brazilian Association of Dentistry, Brasília, DF.***OBJECTIVES**

The objective of this study was to evaluate the capacity and ease of use of the new bioceramic cements.

METHOD

After an endodontic treatment, a 67-year-old female patient with a symptomatic right upper central incisor was evaluated in a private endodontic clinic. The patient reported spontaneous pain. Clinical examination showed an abscess with fistula, the tooth was sensitive to percussion and palpation. Cold sensitivity test was negative. After radiographic examination, apical resorption was observed. Cone-beam computed tomography (CBCT) was conducted and showed apical resorption in the two central incisors # 8. Root canals were instrumented with Root Zx 2 (J Morita Corp., Irvine, CA, USA) and Endosequence rotary files 35.04 to 50.04 (Brasseler, Savannah, GA, USA) using 2.5% sodium hypochlorite and EDTA as well as ultrasonic tip 20.01 (Helse Ultrasonic, Ocoee, FL, USA). Calcium hydroxide was used as dressing for 14 days and. After symptom remission, an apical plug was made with the new bioceramic product BIO-C® REPAIR (Angelus, Londrina, PR, Brazil). The root canals were filled with the new ready-to-use, BIO-C® SEALER (Angelus, Londrina, PR, Brazil) and single gutta-percha cones 50.04 (Tanari, Tanari, Manacapuru, AM, Brazil). The cones were cut with a heat transfer system and condensed.

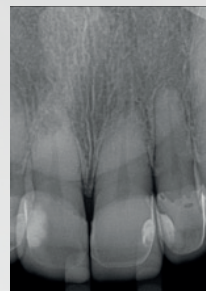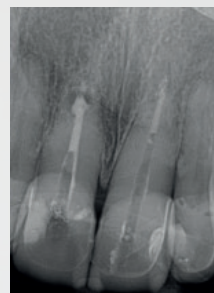
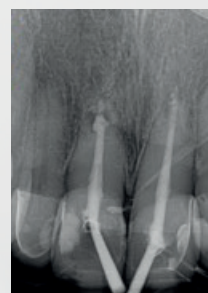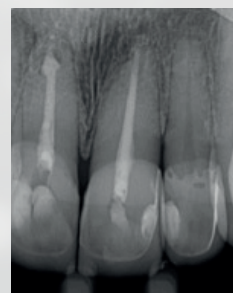
CONCLUSION

According to the results, it is concluded that BIO-C® REPAIR and BIO-C® SEALER are efficient when used in resorption repair and root canal filling, respectively.

REFERENCES

Guo, Y.J.; Du, T.F.; Li, H.B.; Shen, Y.; Mochubon, C.; Hleaway, A.; Wang, Z.J.; Ma, J.; Haapsalo, M., "Physical properties and hydration behavior of a fast-setting bio-ceramic endodontic material", 2016; 20(16): 23.

Wang, Z., "Bioceramic materials in Endodontics", *Endodontic Topics*, 2015; 32, 3-30.

Figure 1 - Initial radiograph (Teeth # 8 and 9)**Figure 2 - Apical cap with BIO-C® REPAIR****Figure 3 - Gutta-percha cones and BIO-C® SEALER****Figure 4 - Final radiography**

Clinical Case 4

Regenerative endodontic surgical procedure using ready-to-use Bioceramic material: clinical case report

Dr Renato Interliche

*Cirurgião dentista pela Universidade Estadual de Londrina(1996)
Especialista em Endodontia pelo Associação Odontológica do
Norte do Paraná(1997)
Mestre em Odontologia (Endodontia) pela Universidade de Ri-
beirão Preto(2005).*

ABSTRACT

The use of bioceramics as a material of choice for retrofilling in endodontic surgery is justified due to its regenerative action on bone tissue, its ease of handling during the surgical procedure, excellent sealing properties, and good moisture tolerance. In the clinical case presented, the rapid repair of the periapical region is evidenced with the use of a bioceramic retrofilling material (Bio-C Repair).

INTRODUCTION

The search for appropriate materials for regeneration and sealing of the apical region in cases of endodontic surgery has always been a challenge in Endodontics.

When materials based on aggregated trioxide mineral appeared, part of the difficulties encountered with previous materials was resolved, as these materials have hydrophilic characteristics and can be used in humid places, and also with high sealing power due to their expansion of setting.

These materials have evolved significantly in recent years, even receiving a new name – Bioceramics. This term was introduced to address MTA-based materials modified from their original form.

The biggest change among them was to reduce the particle size which gives the material a greater reactivity with the tissues, leading to a shorter repair time.

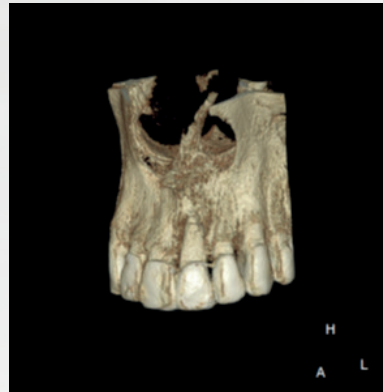Today, ready-to-use materials, such as the one illustrated in this clinical case, also bring greater practicality to the use and optimization of the amount of material used, since products that are in powder/liquid form always have leftovers on hand or capsule mixing.

Another characteristic of this new material is that it will not be influenced by the operator regarding its physicochemical characteristics, as it does not depend on hand mixing, and the powder/liquid ratio.

CLINICAL CASE DESCRIPTION

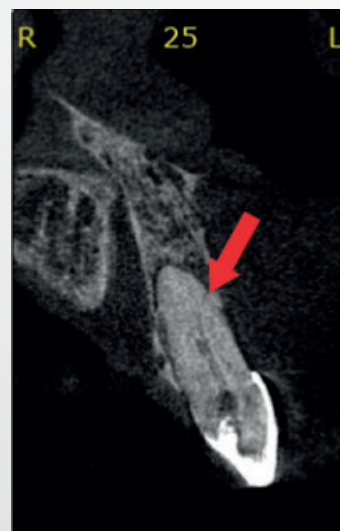The E.A.V. patient, male, 41 years old, Caucasian, without compromising overall health was referred to private practice for evaluation and treatment of tooth 9 that had chronic apical periodontitis with active fistula.

Figure 1 - Tomographic image showing extensive apical bone destruction and total loss of the cortical bone buccal wall in tooth 9



After conventional non-surgical endodontic treatment, it did not present regression of the lesion. During treatment, an anatomical variation was also found in the apical region of the tooth in question. This variation was confirmed by cone-beam computed tomography exam before the surgical treatment.

Figure 2 - Tomographic image in sagittal reconstruction showing the anatomical variation and lateral-end (distobuccal) of the apical foramen.



The surgery was performed according to the following steps:

- anesthesia (articaine 4%);
- L-shaped marginal incision (from tooth 23 to 11) and total flap detachment;
- removal of the periapical lesion and apicectomy

(ultrasound to cut the apical portion of the tooth)
(Bladesonic insert – Helse ultrasonic);

- hemostasis of the cavity with collagen fiber;
- Apical preparation (ultrasound) (P1M insert – Helse ultrasonic);
- retrofilling with Bio-C Repair (Angelus);
- suture;
- final x-ray.

For the patient, antibiotic therapy was prescribed for 5 days, analgesics and mouthwashes with chlorhexidine (2.0%) for one week.

Follow-ups were carried out monthly until the 6th month, where it was possible to notice a marked improvement in the bone condition of the region.

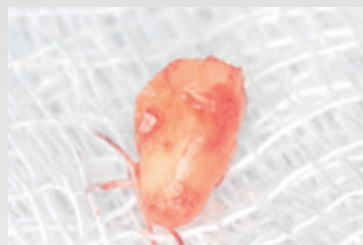
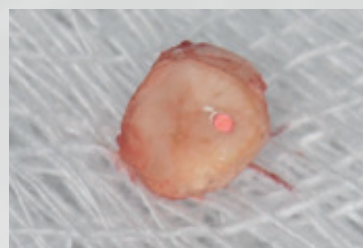


Figure 3 - Periapical radiograph immediately after retrofilling. Trans surgical.

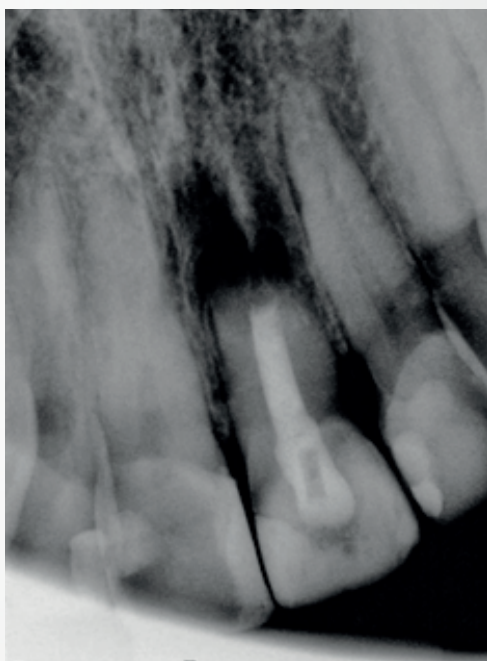


Figure 4 - Images of the apical portion removed during periapical surgery.

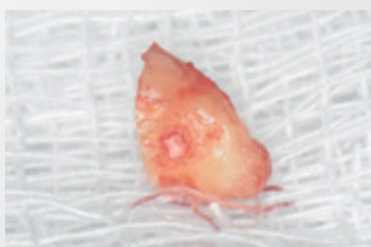


Figure 5 - Control radiographic image – 2 months. Note the beginning of bone repair

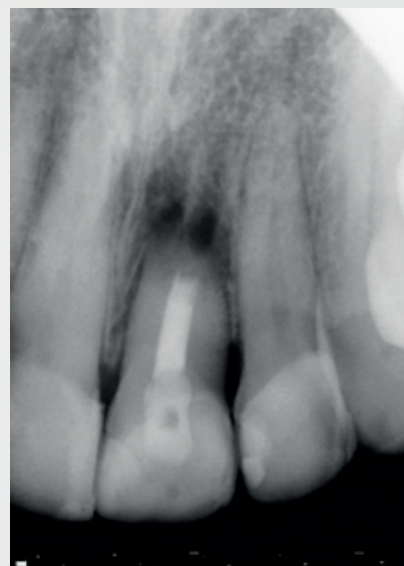
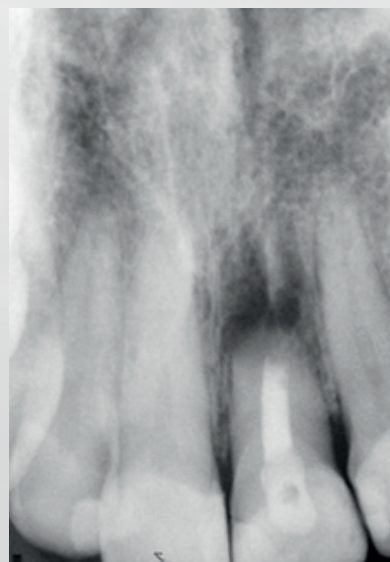


Figure 6 - Control radiographic image – 6 months. Note bone repair in progress.



DISCUSSION

Endodontic apical surgery is a procedure indicated for cases where non-surgical endodontic treatment has not resulted in success.

Currently, endodontic surgeries with greater predictability of success are those that include apicectomy, retropreparation and retrofilling. In other words: the periapical lesion and the apical portion of the root are removed, a retro-preparation is carried out with ultrasonic inserts and this preparation is sealed with materials suitable for this purpose.

The association between the operating microscope and ultrasound considerably improved the prognosis of this type of treatment.

Added to this equipment, the introduction of materials with excellent sealing characteristics and biocompatibility for performing retrofilling. The MTA, introduced by Torabinejad, stands out, where there was a significant evolution in this stage of endodontic surgeries.

A change in the level of retrofilling, following the introduction of MTA, was the use of ready-to-use materials, such as Bio-C Repair presented in this case, where the ease of use and physicochemical properties considerably help the resolution of clinical cases.

In cases like the one presented here, bone gain in a short time makes us believe that the total healing of the periapical pathology is just a matter of time. Periodic checks will be performed every six months, as the patient no longer has any clinical signs (swelling, fistula or mobility) nor symptoms (pain or discomfort when biting).

The decontamination obtained by surgically removing the apical portion is a major factor in the healing process. However, the chemical properties of the retro-obturator material must be taken into account, since the release of calcium ions (Ca^{2+}) significantly favors bone formation.

It is also worth noting the antimicrobial power of the material obtained by the release of hydroxyls that raise the pH, which has a strong participation in the decontamination of the region.

CONCLUSION

Bioceramic materials are recognized for their high degree of bioactivity, and regeneration. Conditions where large bone losses are observed, which were difficult to resolve, today are cases of accelerated repair and with a very favorable prognosis, as in the clinical case described.

REFERENCES

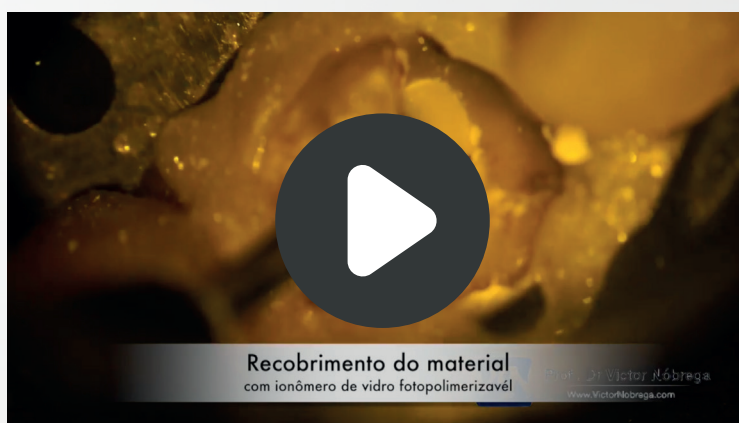- AKCAY, M. et al. Dentinal tubule penetration of AH Plus, iRoot SP, MTA fillapex, and guttaflow bioseal root canal sealers after different final irrigation procedures: A confocal microscopic study. *Lasers in Surgery and Medicine*, v. 48, n. 1, p. 70-76, 2016.
- BROON, N. J. et al. Respuesta inflamatoria de Bioceramic a la implantación de tubos de dentina en tejido subcutáneo de ratas. *Revista Odontológica Mexicana*, v. 20, n. 3, p. 174-178, 2016.
- BUENO, C. R. E. et al. Biocompatibility and biomineralization assessment of bio-ceramic-, epoxy-, and calcium hydroxide-based sealers. *Brazilian Oral Research*, v. 30, n. 1, 2016.
- CARVALHO, C. N. et al. Micropush-out dentin bond strength and bioactivity analysis of a bioceramic root canal sealer. *Dental Materials*, v. 29, p. e79, 2013.
- HAN, L.; OKIJI, T. Bioactivity evaluation of three calcium silicate based endodontic materials. *International Endodontic Journal*, v. 46, n. 9, p. 808-814, 2013.
- KOHLI, M. R. et al. Spectrophotometric analysis of coronal tooth discoloration induced by various bioceramic cements and other endodontic materials. *Journal of Endodontics*, v. 41, n. 11, p. 1862-1866, 2015.
- LIMA, NFF et al. Cimentos biocerâmicos em endodontia: revisão de literatura. *Revista da Faculdade de Odontologia-UPF*, v. 22, n. 2, 2017.
- LIU, S.; WANG, S.; DONG, Y. Evaluation of a bioceramic as a pulp capping agent in vitro and in vivo. *Journal of Endodontics*, v. 41, n. 5, p. 652-657, 2015.
- MCMICHAEL, GE; PRIMUS, CM; OPPERMAN, LA. Dentinal tubule penetration of tricalcium silicate sealers. *Journal of Endodontics*, v. 42, n. 4, p. 632-636, 2016.
- SANTOS, J. L. Cimentos Biocerâmicos: breve revisão bibliográfica e apresentação de casos clínicos. 38 f. Monografia para título de especialista em Endodontia - Universidade Norte do Paraná, Londrina, 2018.

VIDEOS

Parendodontics - Professor Victor Nóbrega



Vital Pulp Trepanation Sealing - Professor Victor Nóbrega



BIBLIOGRAPHY

BERNARDES, R.A.; Ready-to-use bioceramic materials in apical resorption: A clinical case. *Roots*, v.1 2018

Abstract

Conclusion: Both products showed the ability and efficiency to be used in repair of resorptions and filling root canals, respectively. - CLINICAL CASE

CASTRO, L.G.S.D.; CIRURGIA PARENDODÔNTICA COM UTILIZAÇÃO DE CIMENTO BIOCERÂMICO – RELATO DE CASO CLÍNICO. Monografia apresentada ao Instituto de Pós-Graduação – THUM – Curso: ESPECIALIZAÇÃO EM ENDODONTIA, para obtenção do título de Especialista em ENDODONTIA. JOINVILLE, 2019

Abstract

The bioceramic cements facilitate the repair of the periapical tissue, sealing perfectly if well applied on the prepared cavity and has easy manipulation and insertion to the desired area. CLINICAL CASE

LOPEZ-GARCIA, S.; ET AL . Biological Effects of New Hydraulic Materials on Human Periodontal Ligament Stem Cells. *J. Clin. Med.* 2019, 8, 1216; doi:10.3390/jcm8081216

Abstract

Bio-C Repair displayed higher cell viability, cell adhesion and migration rates than Bio-C Sealer.

BENETTI, F.; ET AL.; Cytotoxicity, Biocompatibility and Biomineralization of a New Readyfor-Use Bioceramic Repair Material. *Brazilian Dental Journal* (2019) 30(4): 325-332

Abstract

The materials' cytocompatibility was similar at 48h for most dilutions ($p>0.05$). At 7 and 30 days, the groups had moderate and mild inflammation, respectively ($p>0.05$). All materials showed positive structures for von Kossa and polarized light. In conclusion, Bio-C Repair had similar cytocompatibility to MTA-based materials is biocompatible and induces biomineralization.

LOZANO, F.J.R. ET AL.; In Vitro Effect of Putty Calcium Silicate Materials on Human Periodontal Ligament Stem Cells. *Appl. Sci.* 2020, 10, 325;

Abstract

The results suggest that Bio-C Repair and TotalFill BC RRM putty are biologically appropriate materials to be used as retrograde obturation material. BIOLOGICAL PROPERTIES

LOPEZ-GARCIA, S.; ET AL. Biological Effects of New Hydraulic Materials on Human Periodontal Ligament Stem Cells. J. Clin. Med. 2019, 8, 1216; doi:10.3390/jcm8081216

Abstract

Moreover, SEM showed abundant cells adhered on Bio-C Repair and a moderate number of cells attached on Bio-C Sealer. Finally, EDX analysis identified higher percentages of Ca and O in the case of Bio-C repair than with Bio-C sealer, while other elements such as Zr and Si were more abundant in Bio-C sealer. Conclusions: Bio-C Repair displayed higher cell viability, cell adhesion and migration rates than Bio-C Sealer

BENETTI, F.; ET AL. Cytotoxicity, Biocompatibility and Biomineralization of a New Readyfor-Use Bioceramic Repair Material. Brazilian Dental Journal (2019) 30(4): 325-332

Abstract

Bio-C Repair had similar cytocompatibility to MTA-based materials is biocompatible and induces biomineralization.

INTERLICHE, R; ET AL. Case report: The use of Bio-C Sealer and Bio-C Repair in periapical surgery. <<<https://us.dental-tribune.com/clinical/case-report-the-use-of-bio-c-sealer-and-bio-c-repair-in-periapical-surgery/>>>

Abstract

This case report aims to present a clinical case in which periapical surgery with root-end filling was performed with the use of new bioceramic-based sealers. The ease handle of these materials was verified as well as a fast bone repair in a short period. It was concluded, and, if the results are maintained in the long term, these sealers may be the first choice for these clinical procedures.

ABRÃO, S.M.S. BIOCOMPATIBILIDADE DO BIO-C REPAIR EM COMPARAÇÃO COM TRÊS OUTROS CIMENTOS ENDODÔNTICOS REPARADORES – ESTUDO IN VITRO. Dissertação apresentada ao Programa de Pós- Graduação Stricto Sensu da Universidade Norte do Paraná - UNOPAR, como requisito parcial à obtenção do título de Mestre em Odontologia LONDRINA, 2020

Abstract

The classic bioceramic cements are more biocompatible than the ready-to-use ones, however, the BCR showed better results than the similar one, ERRM.

GIRELLI, C.F.M.; ET AL. The importance of bioceramics and computed tomography in the late clinical management of a horizontal root fracture: A case report. Clin Exp Dent. 2020;12(5):e514-8.

Abstract

Pulp necrosis was diagnosed and CBTC was requested for treatment planning. Subsequently, endodontic treatment was performed using a bioceramic apical plug. A 2-year follow-up indicated the absence of root resorption and normal periodontal and periapical tissues. It was concluded that endodontic treatment associated with the use of bioceramics and the aid of CBTC is an effective therapeutic option in cases of permanent horizontal root fractures.

PESSOTTI, V.P. Reabsorção Radicular Interna - Relato de um caso clínico NOT PUBLISHED**Abstract**


É de suma importância realizar com atenção uma boa anamnese, exames clínicos e complementares. Pois, quanto mais precoce for o diagnóstico da reabsorção radicular interna, melhor será o prognóstico, diminuindo o risco de fragilização da estrutura dentária. É possível obter um bom resultado clínico a partir de um diagnóstico precoce e um tratamento apropriado, permitindo a manutenção do dente no alvéolo. INTERNAL RESORPTION


SERAFIM, A.X.; SILVA, S.C..REABSORÇÃO CERVICAL EXTERNA: relato de caso. Trabalho de Conclusão de Curso apresentado à Universidade Potiguar (UNP); como parte dos requisitos para obtenção do grau de Cirurgião-Dentista. NATAL-2020**Abstract**

A utilização do Bio-C Repair (Angelus) foi decidida após análise de possíveis materiais seladores. Este reparador biocerâmico tem grande êxito em virtude da sua citocompatibilidade, biocompatibilidade, e capacidade de biomineralização similar ao MTA. Além dos benefícios supracitados, merece destaque a sua grande vantagem quando comparado a outros cimentos convencionais, tendo em vista que não requer manipulação, simplificando o procedimento e gerando uma maior economia de tempo de trabalho. CLINICAL CASE

Simplified!

Customer Service
☎ 43 9 9919 0244
+55 43 2101 3200

 /angelusodonto
/angelusodontoglobal

 /AngelusOdonto

www.angelus.ind.br

 **angelus**[®]

 **angelus**[®]
Japan

 **angelus**[®]
USA


PRIMA DENTAL
by  angelus[®]